

# **THE MEDICAL MANAGEMENT OF FIBRODYSPLASIA OSSIFICANS PROGRESSIVA: CURRENT TREATMENT CONSIDERATIONS**

The International Clinical Consortium  
on  
Fibrodysplasia Ossificans Progressiva<sup>1</sup>

May 2011

From The Center for Research in FOP and Related Disorders,  
The University of Pennsylvania School of Medicine, Philadelphia, PA 19104

Corresponding Editor:

Frederick S. Kaplan, M.D.  
Isaac & Rose Nassau Professor of Orthopaedic Molecular Medicine  
The University of Pennsylvania School of Medicine  
Department of Orthopaedic Surgery  
Silverstein Two  
Hospital of the University of Pennsylvania  
3400 Spruce Street  
Philadelphia, Pennsylvania 19104  
Phone 215-349-8726/8727  
Fax: 215-349-5928  
Email: [Frederick.Kaplan@uphs.upenn.edu](mailto:Frederick.Kaplan@uphs.upenn.edu)  
Reprint Requests: [Kamlesh.Rai@uphs.upenn.edu](mailto:Kamlesh.Rai@uphs.upenn.edu)

Associate Editors:

Eileen M. Shore, Ph.D.  
Robert J. Pignolo, M.D., Ph.D.

[Kaplan FS, Shore EM, Pignolo RJ (eds), name of individual consortium member, and The International Clinical Consortium on FOP. The medical management of fibrodysplasia ossificans progressiva: current treatment considerations. **Clin Proc Intl Clin Consort FOP** 4:1-100, 2011]

<sup>1</sup>See Section **X** (pages 84-100) for Complete Author Listing.

<b>ABSTRACT.....</b>	<b>5</b>
<b>I. THE CLINICAL AND BASIC SCIENCE BACKGROUND OF FOP.....</b>	<b>6</b>
A. Introduction.....	6
B. Classic Clinical Features of FOP.....	6
C. Other Skeletal Anomalies in FOP.....	6
D. Radiographic Features of FOP.....	7
E. Histopathology of FOP Lesions.....	7
F. Laboratory Findings in FOP.....	8
G. The Immune System & FOP.....	8
H. Misdiagnosis of FOP.....	8
I. Epidemiologic, Genetic & Environmental Factors in FOP.....	9
J. FOP & the BMP Signaling Pathway.....	9
K. The FOP Gene.....	9
L. Structural and Functional Consequences of the FOP Mutation.....	10
M. Genetic Testing & FOP.....	10
N. Animal Models of FOP.....	10
O. Challenges of Therapeutic Assessment in FOP.....	11
<b>II. THE PATHOLOGIC &amp; PATHOLOGIC-BASED TREATMENT OF FOP.....</b>	<b>12</b>
A. Introduction.....	12
B. Corticosteroids.....	12
C. Mast Cell Inhibitors.....	13
D. Cyclo-oxygenase-2 Inhibitors & NSAIDs.....	15
E. Aminobisphosphonates.....	17
F. Acute & Chronic Pain Management in FOP.....	23
G. Muscle Relaxants.....	24
H. Chemotherapy Agents & Radiation Therapy.....	24
I. Bone Marrow Transplantation.....	24
J. Rosiglitazone.....	25
K. Retinoic Acid Receptors Agonists.....	27
L. Miscellaneous Agents.....	29
M. Targeting ACVR1/ALK2; Definitive Targets for Therapy.....	29
<b>III. SPECIAL MEDICAL CONSIDERATIONS.....</b>	<b>31</b>
A. Introduction.....	31
B. Injury Prevention in FOP.....	31
C. Spinal Deformity in FOP.....	32
D. Cardiopulmonary Function in FOP.....	33
E. Immunizations & FOP.....	34
F. Limb Swelling & FOP.....	38
G. Pressure Sores in FOP.....	38
H. Fractures in FOP.....	39
I. Preventive Oral Healthcare in FOP.....	39
J. Dental Anesthesia in FOP.....	40
K. General Anesthesia in FOP.....	40
L. Orthodontics in FOP.....	42

M. Submandibular Flare-ups of FOP.....	42
N. Hearing Impairment in FOP.....	44
O. Kidney Stones & FOP.....	44
P. Rehabilitation Issues in FOP .....	44
Q. Pregnancy Issues in FOP.....	46
<b>IV. CURRENT TREATMENT CONSIDERATIONS.....</b>	<b>48</b>
<b>V. CLASSES OF MEDICATIONS (TABLE 1) .....</b>	<b>50</b>
i. Class I Medications.....	50
ii Class II Medications.....	52
iii. Class III Medications.....	53
<b>VI. SUMMARY OF KEY PRACTICE POINTS.....</b>	<b>54</b>
<b>VII. CONCLUSIONS.....</b>	<b>56</b>
<b>VIII. ACKNOWLEDGEMENTS .....</b>	<b>57</b>
<b>FIGURE 1: SYMPTOMATIC TREATMENT SCHEMA IN FIBRODYSPLASIA OSSIFICANS PROGRESSIVA (FOP) .....</b>	<b>58</b>
<b>IX. REFERENCES.....</b>	<b>59</b>
<b>I. The Clinical and Basic Science Background of FOP.....</b>	<b>59</b>
A. Introduction.....	59
B. Classic Clinical Features of FOP.....	59
C. Other Skeletal Anomalies in FOP.....	60
D. Radiographic Features of FOP.....	60
E. Histopathology of FOP Lesions.....	60
F. Laboratory Findings in FOP.....	61
G. The Immune System.....	62
H. Misdiagnosis in FOP.....	62
I. Epidemiologic, Genetic & Environmental Factors in FOP.....	62
J. FOP & The BMP Signaling Pathway.....	63
K. The FOP Gene.....	64
L. Structural and Functional Consequences of the FOP Mutation.....	65
M. Genetic Testing in FOP.....	66
N. Animal Models in FOP .....	66
O. Challenges of Therapeutic Assessment in FOP .....	67
<b>II. THE PATHOLOGIC AND PATHOPHYSIOLOGIC–BASED         TREATMENT OF FOP.....</b>	<b>69</b>
A. Introduction.....	69
B. Corticosteroids.....	69
C. Mast Cell Inhibitors.....	69
D. Cyclo-oxygenase 2 inhibitors & NSAIDS.....	70
E. Aminobisphosphonates.....	71

F. Acute & Chronic Pain Management in FOP.....	73
G. Muscle Relaxants.....	73
H. Chemotherapy Agents & Radiation Therapy.....	74
I. Bone Marrow Transplantation .....	74
J. Rosiglitazone.....	74
K. Retinoic Acid Receptor Agonists.....	75
L. Miscellaneous Agents.....	75
M. Targeting ACVR1/ALK2: Definitive Targets for Therapy .....	76
 III. SPECIAL MEDICAL CONSIDERATIONS.....	 77
A. Introduction.....	77
B. Injury Prevention in FOP.....	77
C. Spinal Deformity in FOP.....	77
D. Cardiopulmonary Function in FOP.....	77
E. Immunizations & FOP.....	77
F. Limb Swelling & FOP.....	78
G. Pressures Sores in FOP.....	79
H. Fractures in FOP.....	79
I. Preventive Oral Healthcare in FOP.....	79
J. Dental Anesthesia in FOP.....	80
K. General Anesthesia in FOP.....	80
L. Orthodontics & FOP.....	80
M. Submandibular Flare-ups in FOP.....	80
N. Hearing Impairment in FOP.....	80
O. Kidney Stones & FOP.....	80
P. Rehabilitation Issues in FOP.....	81
Q. Pregnancy Issues in FOP.....	81
 IV. SUMMARY OF KEY PRACTICE POINTS.....	 82
 V. CONCLUSIONS.....	 83
 X. THE INTERNATIONAL CLINICAL CONSORTIUM ON FIBRODYSPLASIA OSSIFICANS PROGRESSIVA.....	  84

## ABSTRACT

Fibrodysplasia ossificans progressiva (FOP) is a rare and disabling genetic condition characterized by congenital malformations of the great toes and progressive heterotopic endochondral ossification (HEO) in specific anatomic patterns. FOP is the most catastrophic disorder of HEO in humans. Flare-ups are episodic; immobility is cumulative.

A recurrent mutation in activin receptor IA/activin-like kinase-2 (ACVR1/ALK2), a bone morphogenetic protein (BMP) type I receptor, exists in all sporadic and familial cases of classic FOP. The discovery of the FOP gene establishes a critical milestone in understanding FOP, reveals a highly conserved therapeutic target in the BMP signaling pathway, and propels approaches for developing novel inhibitors of ACVR1/ALK2-mediated BMP signaling. While effective therapies for FOP will likely be based on interventions that modulate overactive ACVR1/ALK2 signaling, or specifically block postnatal HEO, present management is focused on early diagnosis, assiduous avoidance of injury or iatrogenic harm, symptomatic amelioration of painful flare-ups, and optimization of residual function.

Here, we briefly review the clinical and basic science background of FOP, the scientific basis for the use of various medications, special medical considerations, and guidelines for the symptomatic relief of FOP based upon currently available medications and therapies. This report is not intended to present a specific approach for managing the symptoms of FOP, but rather is intended to present views, statements, or opinions of the authors which may be helpful to others who face similar challenges.

Further advances in therapeutics will be based on knowledge of disease mechanisms at the molecular and cellular level, the refinement of genetically-based animal models for drug testing, and rigorous clinical trials to assess novel and emerging treatment and prevention strategies.

# **I. THE CLINICAL AND BASIC SCIENCE BACKGROUND OF FOP**

## **A. Introduction**

Here, we provide a brief summary of the clinical and basic science background of FOP in order to place the treatment guidelines that follow into a clinical and scientific context (Kaplan et al., 2005). Detailed references are provided for each subsection in REFERENCES (Section IX). Comprehensive clinical reviews of FOP are available (McKusick, 1972; Connor & Evans, 1982; Smith, 1998; Kaplan et al., 2002; Kaplan et al., 2005; Kaplan et al., 2006; Kaplan et al., 2008; Kaplan et al., 2009).

## **B. Classic Clinical Features of FOP**

Two clinical features define classic FOP: malformations of the great toes and progressive heterotopic endochondral ossification (HEO). Individuals with FOP appear normal at birth except for characteristic malformations of the great toes which are present in all classically affected individuals. During the first decade of life, most children with FOP develop episodic, painful inflammatory soft tissue swellings (or flare-ups). While some flare-ups regress spontaneously, most transform soft connective tissues including aponeuroses, fascia, ligaments, tendons, and skeletal muscles into mature heterotopic bone. Ribbons, sheets, and plates of heterotopic bone replace skeletal muscles and connective tissues through a process of endochondral ossification that leads to an armament-like encasement of bone and permanent immobility. Minor trauma such as intramuscular immunizations, mandibular blocks for dental work, muscle fatigue, blunt muscle trauma from bumps, bruises, falls, or influenza-like viral illnesses can trigger painful new flare-ups of FOP leading to progressive heterotopic ossification (reviewed in Kaplan et al., 2008). Attempts to surgically remove heterotopic bone risk provoking explosive and painful new bone growth.

Heterotopic ossification in FOP progresses in characteristic anatomic and temporal patterns that mimic the patterns of normal embryonic skeletal formation. Heterotopic ossification typically is first seen in the dorsal, axial, cranial, and proximal regions of the body and later seen in the ventral, appendicular, caudal, and distal regions (Cohen et al., 1993). Several skeletal muscles including the diaphragm, tongue, and extra-ocular muscles are spared from FOP. Cardiac muscle and smooth muscle are spared from heterotopic ossification.

Bone formation in FOP is episodic, but disability is cumulative (Rocke et al., 1994). Most patients with FOP are confined to a wheelchair by the third decade of life, and require lifelong assistance in performing activities of daily living. Severe weight loss may result following ankylosis of the jaw. Pneumonia or right-sided heart failure may complicate rigid fixation of the chest wall. The severe disability of FOP results in low reproductive fitness, and fewer than ten multigenerational families are known worldwide. The median age of survival is approximately 40 years, and death often results from complications of thoracic insufficiency syndrome (Kaplan & Glaser, 2005; Kaplan et al., 2010).

## **C. Other Skeletal Anomalies in FOP**

While malformation of the great toes is characteristic of FOP, other developmental anomalies are frequently observed, particularly in the thumbs and cervical spine. Stiffness of the neck is an early

finding in most patients and can precede the appearance of HEO at that site. Characteristic anomalies of the cervical spine include large posterior elements, tall narrow vertebral bodies, and fusion of the facet joints between C2 and C7. Although the cervical spine often becomes ankylosed early in life, any minimal residual movement may eventually result in painful arthritic symptoms (Schaffer et al., 2005).

Other skeletal anomalies associated with FOP include short malformed thumbs, clinodactyly, short broad femoral necks, and proximal medial tibial osteochondromas (Deirmengian et al., 2008; Kaplan et al., 2009).

#### **D. Radiographic Features of FOP**

Radiographic and bone scan findings suggest normal modeling and remodeling of the heterotopic skeleton (Kaplan et al., 1994). Nevertheless, multiple subtle skeletal abnormalities and joint malformations are often seen in individuals with FOP (see section I.C), and the following plain radiographs can aid in rapid phenotypic screening and clinical diagnosis:

- Anterior-Posterior (AP) of both hands
- AP of both feet
- Lateral of cervical spine
- AP & lateral of chest
- AP of pelvis
- AP & lateral of both knees

Bone scans are abnormal before HO can be detected by conventional radiographs. Computed tomography and magnetic resonance imaging of early lesions have been described. While these evaluation methods are generally superfluous from a diagnostic standpoint, they can provide a useful and three-dimensional perspective of the disease process (Reinig et al., 1986). The definitive diagnosis of FOP can be made by simple clinical evaluation that associates rapidly appearing soft tissue lesions with malformations of the great toes (Mahboubi et al., 2001; Kaplan et al., 2005).

#### **E. Histopathology of FOP Lesions**

The histopathology of FOP lesions has been well-described (Kaplan et al., 1993; Gannon et al., 1998; Hegyi et al., 2003; Pignolo et al., 2005). Early FOP lesions contain an intense mononuclear and perivascular infiltration of macrophages, mast cells, and lymphocytes. The precise role of these cells in the evolution of FOP flare-ups is unknown although focal inflammation from any cause is a known trigger of disease activity. Subsequent migration of mononuclear inflammatory cells into affected muscle precedes widespread death of skeletal muscle.

Following a rapid and destructive inflammatory stage, there is an intense fibroproliferative phase associated with robust angiogenesis and neovascularity. Early fibroproliferative lesions are histologically indistinguishable from aggressive juvenile fibromatosis. As lesions mature, fibroproliferative tissue undergoes an avascular condensation into cartilage followed by a revascularization stage with osteogenesis in a characteristic process of HEO. The resultant new ossicle of heterotopic bone appears histologically normal with mature lamellar bone and often contains marrow elements.

Mast cells have been identified at every histological stage of FOP lesion formation, and are found in much greater abundance compared with normal skeletal muscle and nonlesional FOP muscle. In fact, during the intense fibroproliferative stage of the lesion, mast cells are found at a density much higher than in any other inflammatory myopathy (Gannon et al., 2001).

All stages of histological development are present in an active FOP lesion, suggesting that different regions within the lesion mature at different rates. Although heterotopic bone formation in FOP is similar in some respects to bone formation in embryonic skeletal development and postnatal fracture healing, an important difference is the lack of inflammation in primary skeletal formation.

More recent studies indicate that inflammatory cells of hematopoietic origin may be necessary for the induction of heterotopic ossification (Kaplan et al., 2007) and contribute to the late osteogenic stage (Suda et al., 2009), while multipotent stem-like cells of vascular origin contribute to the fibroproliferative, chondrogenic and osteogenic stages of heterotopic ossification (Lounev et al., 2009, Medici et al., 2010; Horwitz, 2010).

## **F. Laboratory Findings in FOP**

Routine biochemical evaluations of bone mineral metabolism are usually normal, although the serum alkaline phosphatase activity and the erythrocyte sedimentation rate (ESR) may be increased, especially during disease flare-ups (Lutwak, 1964). C-reactive protein elevations are a more specific test than ESR for monitoring the acute inflammatory phase of heterotopic ossification after spinal cord injury, but has not been studied in FOP (Estrores et al., 2004). Urinary basic fibroblast growth factor levels may be elevated during disease flare-ups coinciding with the pre-osseous angiogenic phase of early fibroproliferative lesions (Kaplan et al., 1998). Circulating osteogenic cells may also herald early heterotopic bone formation, but remain a research tool (Suda et al. 2009).

## **G. The Immune System & FOP**

Evidence from all levels of investigation suggests involvement of the innate immune system in FOP. The presence of macrophages, lymphocytes and mast cells in early FOP lesions, macrophage and lymphocyte-associated death of skeletal muscle, flare-ups following viral infections, the intermittent timing of flare-ups, and the beneficial response of early flare-ups to corticosteroids support involvement of the innate immune system in the pathogenesis of FOP lesions (Lanchoney et al., 1995; Kaplan et al., 2005; Kaplan et al., 2007). For further detailed discussion of this important topic, see Section II. I. Bone Marrow Transplantation. Recent experimental studies in murine animal models of FOP strongly support the role of the innate immune system in inducing heterotopic ossification (Yu et al., 2008; Kan et al., 2009; Lounev et al., 2009).

## **H. Misdiagnosis of FOP**

FOP is commonly misdiagnosed as aggressive juvenile fibromatosis, lymphedema, or soft tissue sarcoma. Clinicians often fail to associate the rapidly developing soft tissue swellings that appear on the head, neck, and upper back with the malformed great toes. The misdiagnosis of FOP approaches 90 per cent of affected individuals worldwide (Kitterman et al., 2005). Children often undergo unnecessary and harmful diagnostic biopsies that exacerbate the progression of the condition (Zaghloul et al., 2008). This can be particularly dangerous at any anatomic site, but especially so in the neck, back, and jaw where asymmetric



HEO can lead to rapidly progressive spinal deformity, exacerbation of thoracic insufficiency syndrome, or rapid ankylosis of the temporomandibular joints. The high rate of misdiagnosis of FOP may be due, at least in part, to the inadequate descriptions of FOP in most textbooks of medicine, pediatrics, oncology and podiatry. The correct diagnosis of FOP can be made clinically even before radiographic evidence of heterotopic ossification is seen, if soft tissues lesions are associated with symmetrical malformations of the great toes.

## **I. Epidemiologic, Genetic & Environmental Factors in FOP**

FOP is rare with a worldwide prevalence of approximately one in two million individuals. There is no ethnic, racial, gender, or geographic predisposition (Shore et al., 2005; Morales-Piga & Kaplan, 2010). Most cases arise as a result of a spontaneous new mutation. A paternal age effect has been reported (Rogers & Chase, 1979). When observed, genetic transmission is autosomal dominant and can be inherited from either mothers or fathers (Kaplan et al., 1993). Maternal mosaicism may exist (Janoff et al., 1996). Fewer than ten small multigenerational families are known worldwide (Shore et al., 2005). Phenotypic heterogeneity is observed (Janoff et al., 1995; Virdi et al., 1999).

Both genetic and environmental factors affect the phenotype of FOP. A study of three pairs of monozygotic twins with FOP found that within each pair, congenital toe malformations were identical. However, postnatal heterotopic ossification varied greatly depending on life history and environmental exposure to viral illnesses and to soft tissue trauma. Genetic determinants strongly influence disease phenotype during prenatal development while environmental factors strongly influence postnatal progression of heterotopic ossification (Hebela et al., 2005).

## **J. FOP & the BMP Signaling Pathway**

The classic and consistent FOP phenotype of great toe malformations and progressive HEO suggested that the primary molecular pathology might involve the bone morphogenetic protein (BMP) signaling pathway (Kaplan et al., 1990). A number of seminal discoveries provided evidence of profound dysregulation of the BMP signaling pathway in cells from FOP patients (Shafritz et al., 1996; Roush, 1996; Gannon et al., 1997; Ahn et al., 2003; Glaser et al., 2003; Hegyi et al., 2003; Serrano de la Peña et al., 2005; Fiori et al., 2006; Shore et al., 2006; Kaplan et al., 2007; O'Connell et al., 2007; Billings et al., 2008; Shen et al., 2009).

## **K. The FOP Gene**

In order to identify the chromosomal locus for the FOP gene, a conservative genome-wide linkage analysis was conducted using a subset of five families with the most stringent and unambiguous features of FOP. This approach linked FOP to the chromosome 2q23-24 region. The gene encoding activin receptor type IA/activin-like kinase 2 (ACVR1/ALK2), a BMP type I receptor, was identified in the linkage interval. DNA sequencing of the ACVR1/ALK2 gene determined that a recurrent heterozygous missense mutation in the glycine-serine (GS) activation domain (c.617G>A;R206H) occurs in all sporadic or familial classically affected individuals (Shore et al., 2006; Couzin, 2006; Kaplan, 2006; Kaplan et al., 2007; Kaplan et al., 2009; Shore & Kaplan, 2010). Recently, additional mutations have been identified in the GS-domain and kinase domain of ACVR1 in individuals with atypical forms of FOP (Furuya et al., 2008; Kaplan et al., 2008; Shore & Kaplan, 2008; Bocciardi et al., 2009; Kaplan et al., 2009; Petrie et al., 2009; Gregson et al., 2010). Noggin mutations have been reported but are erroneous (Xu M., et al., 2000).

## **L. Structural and Functional Consequences of the FOP Mutation**

Protein homology modeling of the mutated ACVR1/ALK2 receptor predicts destabilization of the glycine-serine (GS) activation domain, consistent with an overactive BMP signaling pathway as the underlying cause of the ectopic chondrogenesis, osteogenesis, and joint fusions seen in FOP (Shore et al., 2006; Groppe et al., 2007). The identified mutation is consistent with previous findings of increased BMP signaling pathway in FOP cells and provides a rational basis for understanding both the postnatal heterotopic ossification and the congenital skeletal malformations that are ignominious signatures of this devastating disease. Models of protein structure are being developed to understand both inter- and intramolecular interactions of the mutant receptor (Groppe et al., 2007).

The GS domain of all BMP type I receptors is a critical site for binding and activation of pathway-specific Smad signaling proteins and is a binding site of FKBP12 (also called FKBP1A), an inhibitory protein that prevents uninhibited low-level constitutive activation of the BMP type I receptor in the absence of ligand (Wang et al., 1996; Chen et al., 1997). FKBP12 also recruits a Smad – Smurf ubiquitin ligase complex that regulates the concentration of the receptor at the membrane (Yamaguchi et al., 2006). Leaky activation of BMP signaling and accumulation of BMP type I receptors at the cell membrane in FOP cells supports aberrant association with FKBP12 in FOP (reviewed in Kaplan et al., 2007). FKBP12 binding to the GS domain is altered, leading to promiscuous ACVR1/ALK2 activity (Kaplan et al., 2007; Kaplan et al., 2008; Shen et al., 2009; Kaplan et al., 2009; van Dinther et al., 2010; Song et al., 2010; Groppe et al., 2011). Exactly how the R206H mutation in ACVR1/ALK2 specifically perturbs BMP signaling in FOP is presently unknown but could involve dysregulation of BMP receptor oligomerization, internalization, degradation and/or intensity and duration of downstream signaling. This is presently the subject of intense investigation (Fukuda et al., 2009; Kaplan et al., 2009).

## **M. Genetic Testing & FOP**

Definitive genetic testing of FOP is now available and can confirm a diagnosis of FOP prior to the appearance of heterotopic ossification. Clinical suspicion of FOP early in life on the basis of malformed great toes can lead to early clinical diagnosis, confirmatory diagnostic genetic testing (if appropriate), and the avoidance of harmful diagnostic and treatment procedures. Clinicians should be aware of the early diagnostic signs of FOP which are congenital malformation of the great toes and episodic soft tissue swelling even before the appearance of heterotopic ossification. This awareness should prompt genetic consultation and testing (if appropriate) and the institution of assiduous precautions to prevent injury and iatrogenic harm (Kaplan et al., 2008). At the present time, genetic testing is available on a clinical and research basis at several laboratories. Please contact the corresponding author for more information.

## **N. Animal Models of FOP**

Animal models of FOP are important in deciphering the pathophysiology of FOP and in testing possible therapies. Laboratory-generated animal models with some features of FOP have provided the opportunity to better understand the biology of BMP-associated heterotopic ossification and to study the effectiveness and safety of currently available and emerging therapies (Olmsted et al., 1998; Glaser et al., 2003; Kan et al., 2004; Kaplan et al., 2005; Fukada et al., 2006; Kan et al., 2009; Lounev et al., 2009; Shen et al., 2009). Development of a knock-in mouse model carrying the classic FOP disease-causing mutation in ACVR1/ALK2 will be critical in establishing specificity of treatment for FOP as well as investigating many previously unexplored aspects of the condition. Such a genetically engineered knock-in mouse is presently being developed (Chakkalakal et al., 2008; Chakkalakal et al., 2010).

## O. Challenges of Therapeutic Assessment in FOP

Flare-ups of FOP are sporadic and unpredictable, and there is great individual variability in the rate of disease progression. Several large studies on the natural history of FOP have confirmed that it is impossible to predict the occurrence, duration or severity of an FOP flare-up, although characteristic anatomic patterning has been described. The rarity of FOP and the unpredictable nature of the condition make it extremely difficult to assess any therapeutic intervention, a fact recognized as early as 1918 by Julius Rosenstirn (Rosenstirn, 1918):

*“The disease was attacked with all sorts of remedies and alternatives for faulty metabolism; every one of them with more or less marked success observed solely by its original author but pronounced a complete failure by every other follower. In many cases, the symptoms of the disease disappear often spontaneously, so the therapeutic effect (of any treatment) should not be unreservedly endorsed.”*

These words ring true today as they did when they were written nearly a century ago. Presently, there is no proven effective prevention or treatment for FOP. With the discovery of the FOP gene and emerging understanding of the pathology and molecular genetics of FOP, new pharmacologic strategies will emerge to definitively treat FOP (Kaplan et al., 2007; Kaplan et al., 2008; Yu et al., 2008; Kaplan et al., 2009). Presently, physicians are faced with an increasing number of potential medical interventions. Unfortunately, clinical experience using these medications for FOP is mostly anecdotal (see sections II. H & II. K.)

The gold standard for all medication studies is a double-blinded randomized placebo-controlled study (Hellman & Hellman, 1991; Passaman; 1991; Miller & Rosenstein, 2003; Auerbach et al., 2007). Although such studies would be difficult to conduct in the FOP community considering the few patients afflicted with the disorder, the erratic natural history of the disease, and the extreme interpersonal and intrapersonal variability of FOP, such a design still remains the best approach for obtaining unambiguous answers to our most perplexing dilemma - the proper assessment of true therapeutic utility. Future studies urgently need to consider this approach although, like any approach, it too has its pitfalls. FOP's extreme rarity, variable severity, and fluctuating clinical course pose daunting uncertainties when evaluating experimental therapies.

In the next section of this report, we will review the major classes of medications that have been used (and that are being used) to manage symptoms in patients who have FOP, and we will provide a perspective on indications and contraindications for the use of such medications until more specific disease-modifying medication and therapies are available.

## II. THE PATHOLOGIC AND PATHOPHYSIOLOGIC-BASED TREATMENT OF FOP

We emphasize that this report reflects the authors' experience and opinions on the various classes of symptom-modifying medications, and is meant only as a guide to this controversial area of therapeutics. Although there are common physical features shared by every person who has FOP, there are differences among individuals that may alter the potential benefits or risks of any medication or class of medications discussed here. The decision to use or withhold a particular medication must ultimately rest with an individual patient and his or her physician.

### A. Introduction

The ultimate treatment of FOP will likely be based on integrated knowledge of the cellular and molecular pathophysiology of the condition. An abbreviated outline of our current knowledge is presented in Figure 1. Several recent reviews of treatment in FOP provide general background references (Glaser & Kaplan, 2005; Kaplan et al., 2008), but interested clinicians are guided to this text for the most recent review of symptomatic treatments.

### B. Corticosteroids

The rational use of corticosteroids early in the course of an FOP flare-up is based primarily on its potent anti-inflammatory effects (Rhen & Cidlowski, 2005) and on emerging knowledge of the importance of inflammatory triggers in FOP flare-ups (Kaplan et al., 2007; Lounev et al., 2009). Widespread favorable anecdotal reports from the FOP community suggest that a brief 4-day course of high-dose corticosteroids, begun within the first 24 hours of a flare-up, may help reduce the intense inflammation and tissue edema seen in the early stages of the disease.

The use of corticosteroids should be restricted to:

1. The extremely early symptomatic treatment of flare-ups that affect:
  - Major joints
  - The jaw
  - The submandibular area
2. The prevention of flare-ups following major soft tissue injury (severe trauma)
3. The prevention of flare-ups in emergent, elective, and minor surgeries such as dental surgery, hypospadias repair, appendectomies, etc. (peri-operative use), and may decrease the likelihood of heterotopic ossification.

Corticosteroids should not generally be used for the symptomatic treatment of flare-ups involving the neck or trunk due to the long duration and recurring nature of these flare-ups, and the difficulty in assessing the true onset of such flare-ups. On rare occasions, a brief course of corticosteroids may be used to break the cycle of recurrent flare-ups often seen in early childhood. However, the utility of this approach is not widely accepted, as flare-ups tend to recur rapidly following cessation of corticosteroid therapy.

Corticosteroids are most effective if used within the first 24 hours of a new flare-up that affects the movement of a major joint, prophylactically following major soft tissue trauma, or peri-operatively as noted above. The dose of corticosteroids is dependent upon body weight. A typical dose of prednisone is 2 mg/kg/day (up to 100 mg), administered as a single daily dose for no more than 4 days (Table 1). In order to have the least suppressive effect on the hypothalamic-pituitary-adrenal axis, the medication should be given in the morning.

Alternatively, high dose intravenous corticosteroid pulse therapy may be considered, but must be performed with an inpatient hospitalization to monitor for potentially dangerous side-effects of hypertension (Table 1). When prednisone is discontinued, a non-steroidal anti-inflammatory medication or cox-2 inhibitor (in conjunction with a leukotriene inhibitor) may be used symptomatically for the duration of the flare-up (Table 1). Corticosteroids should not be used for the long-term chronic treatment of FOP as chronic dependence due to adrenal suppression and other steroid-associated side-effects will likely result.

Corticosteroids are an important component in the management of a submandibular flare-up of FOP. Submandibular swelling in patients who have FOP can be a medical emergency and requires intensive precautionary measures to avoid catastrophic clinical deterioration. These measures include early identification of the submandibular flare-up, avoidance of lesional manipulation, airway monitoring, aspiration precautions, nutritional support due to the difficulty in swallowing, and the use of corticosteroids. The potentially dangerous nature of flare-ups in the submandibular region and jaw may dictate a slightly longer use of corticosteroids with an appropriate taper for the duration of the flare-up or until the acute swelling subsides (Janoff et al., 1996; see section II. M).

While patients are encouraged to contact their physician at the earliest sign of a flare-up, many find it comforting to have a supply of prednisone on hand at home in case of an emergency. This “pill in the pocket” approach has been feasible and safe with a monitored reduction in emergency room and hospital visits.

### **C. Mast Cell Inhibitors**

Among the most typical features of FOP flare-ups are the intense muscle edema, fibroproliferation, and angiogenesis characteristic of early pre-osseous FOP lesions, and the rapid spread of the lesions into adjacent tissue. As most patients and families know all too well, a lesion may appear within hours and can reach an alarming size literally overnight. The sudden appearance and rapid spread of an FOP lesion suggests involvement of an armada of inflammatory mediators along with an abnormal connective tissue wound response, and points to a potential role for inflammatory mast cells and their mediators in the extension of the disease process.

Mast cells are indigenous cells in the body’s connective tissues and arise from the bone marrow. They circulate through the blood as committed, but not terminally differentiated cells, and migrate into numerous tissues including skeletal muscle where they mature and reside as harmless bystanders until provoked by a traumatic or inflammatory stimulus. Mast cells are found in close proximity to blood vessels and nerves. In normal skeletal muscle, mast cells are found very sparsely distributed in the

connective tissues between the muscle bundles. Mast cells contain granules of very potent stored chemicals that induce edema, fibroproliferation and angiogenesis when released into the surrounding tissue. For many years, the role of mast cells was unknown, but it now appears that they play an important role in tissue repair and wound healing (Kaplan, 2002).

When mast cell recruitment and activation go awry, the process can lead to severe inflammatory reactions. This has long been recognized with mast cell activation in the skin and lungs, resulting in the symptoms of hives and asthma, respectively. However, very little is known about mast cells in the deeper tissues of the body such as the skeletal muscles. Mast cells are not easily visible microscopically unless special stains are used to detect them. Mast cells are stimulated by a myriad of external and internal stimuli such as internal immune responses and external tissue injury.

Mast cells contain granules whose sequestered contents include histamine, heparin, angiogenic proteins, and matrix degrading enzymes that allow injured tissue to repair itself. Potent angiogenic proteins released by mast cells include basic fibroblast growth factor, vascular endothelial growth factor, and transforming growth factor beta. Mast cells also release a litany of inflammation-causing molecules including tumor necrosis factor alpha, prostaglandins, and leukotrienes. Upon release from the mast cells, these substances influence a vast array of biological processes including inflammation, immune function, angiogenesis, fibrous tissue formation, extracellular tissue remodeling, and tissue repair (Kaplan, 2002).

The intense inflammatory muscle edema, fibroproliferation, and angiogenesis characteristic of early pre-ossseous FOP lesions and the rapid spread of these lesions along muscle planes into adjacent tissue suggested a potential role for mast cells in the FOP process. As little is known about the resident mast cells in skeletal muscle, a comprehensive analysis was undertaken of mast cell distribution in normal skeletal muscle, in uninvolved FOP muscle, in FOP lesions, in inflammatory and genetic muscle diseases, and in experimentally-induced animal models of heterotopic ossification (Gannon et al., 2001).

The findings of this study were startling and unexpected. Mobilization and activation of inflammatory mast cells was found at all stages of FOP lesional development. These data documented an important role for mast cells in the pathology of FOP lesions (Gannon et al., 2001).

The following hypothesis was developed based on observations and experimental data in the mast cell study:

Tissue injury in FOP patients leads to macrophage, mast cell, and lymphocyte migration into normally appearing skeletal muscle. Mediators released by mast cells stimulate a cycle of inflammatory edema, fibrosis, and angiogenesis which is potentiated at the leading edge of an advancing FOP lesion. Reactive fibroblasts within the muscle tissue produce proteins which lead to further proliferation of mast cells and a self-sustaining escalation of the disease process known as a flare-up. Eventually, transforming growth factor beta, released by mast cells and connective tissue progenitor cells, limits the lymphocytic recruitment and migration and thus the size and extent of the expanding lesion, while endogenous overactivity of ACVR1/ALK2 in the core of the fibroproliferative lesion drives the lesion towards ossification through an endochondral pathway.

The observation of mast cell mobilization in FOP lesions provides a novel and previously unrecognized opportunity to evaluate anti-mast cell therapies in limiting the spread of FOP lesions. Data from a unique model of BMP implantation into an animal model that is genetically reduced in mast cells suggest that completely blocking mast cell function is not presently possible. However, reduction of mast cell activity may play an important role in limiting the inflammatory component of the process and thus the local extent of the lesional swelling.

Mast cells, macrophages, lymphocytes, and their associated inflammatory-mediators may also be reduced with the use of mast cell stabilizers, long-acting non-sedating antihistamines, leukotriene inhibitors, non-steroidal anti-inflammatory medications, and cox-2 inhibitors. Mast cell membrane stabilizers may reduce the release of angiogenic and chemotactic factors, while anti-histamines and leukotriene inhibitors may reduce the downstream effects of released mediators (Simmons, 2004). The optimal use of these medications and their potential efficacy in FOP is presently unknown. However, general guidelines for their use are provided in Table 1.

#### **D. Cyclo-oxygenase 2 Inhibitors & NSAIDs**

Selective cyclo-oxygenase-2 (cox-2) inhibitors and non-steroidal anti-inflammatory drugs (NSAIDs) medications have important implications for the management of FOP symptoms.

The body produces two types of prostaglandins: “physiological” prostaglandins and “inflammatory” prostaglandins. Physiological prostaglandins are normally produced in many of the body’s tissues and serve to protect organs, such as the stomach, from metabolic injury. Inflammatory prostaglandins are produced in response to injury, and play a major role in the inflammatory response to tissue injury and repair. Traditional NSAIDs such as aspirin, ibuprofen and indomethacin inhibit the formation of both the physiological and inflammatory prostaglandins. The selective cyclo-oxygenase-2 (cox-2) inhibitors primarily inhibit the inflammatory prostaglandins and leave most, but not all, of the physiological prostaglandins relatively intact (Katori & Majima, 2000; Van Ryn & Pairet, 2000).

Inflammatory prostaglandins are potent co-stimulatory molecules along with BMPs in the induction of heterotopic bone. Studies in the orthopaedic literature have shown that lowering inflammatory prostaglandin levels in experimental animals dramatically raises the threshold for heterotopic ossification, thus, making it more difficult for heterotopic bone to form. Animals pretreated with inhibitors of prostaglandin synthesis fail to form heterotopic bone following intramuscular injections of BMP-containing demineralized bone matrix (DiCesare et al., 1991). In contrast, animals treated with prostaglandin inhibitors co-incident with or following an injection of demineralized bone matrix still form heterotopic bone.

These data suggest, that in order for inhibitors of prostaglandin synthesis to be truly effective in preventing heterotopic ossification, the medication must be “in the system” (in other words circulating in the blood at therapeutic levels) before a bone-induction signal occurs. In addition to their potent anti-inflammatory properties, NSAIDs, and cox-2 inhibitors have potent anti-angiogenic properties especially at high dosages, a feature that makes them even more desirable for consideration in FOP.

An important paper published in 2002 showed convincingly that animals genetically engineered to lack both copies of the gene encoding the cox-2 enzyme (cox-2 knockouts) failed to generate new bone formation at a fracture site, thus demonstrating the importance of the cox-2 enzyme in inflammatory bone formation (Zhang et al., 2002). While pharmacologic doses of cox-2 inhibitors (medications that block the activity of the cox-2 enzyme) given to normal animals had a similar effect, the inhibition of bone formation in both sets of animals (cox-2 knockouts and animals treated with cox-2 inhibitors) could be overcome with massive amounts of recombinant BMP, indicating that cox-2 activity occurs upstream of BMP signaling and that overactivity of the BMP pathway (as is seen in FOP) could plausibly overcome a cox-2 blockade (Zhang et al., 2002). Similar results were reported in a separate study published in 2002 (Simon et al., 2002).

Inflammatory prostaglandin levels are dramatically elevated in the urine of patients who have FOP, especially during times of a disease flare-up (Levitz et al., 1992). Inflammatory prostaglandins directly stimulate the induction of angiogenic peptides which can further promote the osteogenic process (Weinreb et al., 1997; Jones et al., 1999). These observations suggest the following hypothesis:

Lowering baseline levels of inflammatory prostaglandins in patients with FOP may raise the threshold for heterotopic ossification even in the presence of promiscuously active ACVR1/ALK2.

Compared to the parent class of NSAIDs, the selective cox-2 inhibitors offer the possibility of a lower gastrointestinal risk profile, although much controversy still exists. Also, the half-life of most of the new cox-2 inhibitors is conducive to a once or twice daily dosage regimen, a factor which may help promote patient compliance (Deeks et al., 2002).

Substantial concerns have been raised about the safety of the cox-2 inhibitors, including rofecoxib (Vioxx), celecoxib (Celebrex), and valdecoxib (Bextra) in patients at high risk of cardiovascular and cerebrovascular disease (White et al., 2002; White et al., 2003; Couzin, 2004; Grosser et al., 2006). Although the cox-2 enzyme is necessary for the synthesis of inflammatory prostaglandins, it also controls the synthesis of prostacyclin, a prostaglandin that is essential for the health and potency of blood vessels, especially in the heart and brain.

On September 30, 2004, Merck & Co. announced voluntary worldwide withdrawal of rofecoxib (Vioxx), based on three-year data from a prospective randomized double-blind placebo-controlled clinical trial to assess the safety and efficacy of high-dose rofecoxib in preventing recurrence of colorectal polyps in patients with a history of colorectal adenomas (Merck & Co., 2004). In the study, there was an increased relative risk for confirmed cardiovascular and cerebrovascular events including heart attack and stroke, beginning after 18 months of treatment in patients taking rofecoxib compared to those taking placebo. The sudden withdrawal of Vioxx by Merck & Co. caused much confusion and concern throughout the FOP community especially for those taking the medication to reduce painful symptoms of FOP.

The voluntary worldwide withdrawal of rofecoxib by Merck & Co. in late September 2004 came less than three weeks after the US Food and Drug Administration (USFDA) approved rofecoxib for use in children with rheumatoid arthritis, and only three weeks after Merck & Co. agreed to fund a USFDA-approved and a University of Pennsylvania Investigational Review Board approved double-blind randomized placebo controlled study to assess the efficacy of rofecoxib in preventing flare-ups in patients who have FOP. That study, of course, will not take place.

Similar concerns have been raised about all cox-2 inhibitors including celecoxib and valdecoxib. Editorials published in **The New England Journal of Medicine**, carefully outlined the data, the controversies, and the possible alternatives for patients and physicians (Fitzgerald, 2004; Topol, 2004). Before the recent studies showing increased cardiovascular risk for rofecoxib and celecoxib were confirmed, the scientific evidence of decreased gastrointestinal events from the cox-2 inhibitors (compared to NSAIDs) in several trials clearly outweighed the evidence of cardiovascular risk. Selective cox-2 inhibitors remain a rational choice for patients at low cardiovascular risk who have had serious gastrointestinal events or in patients who are at high risk of serious gastrointestinal events, such as those with FOP who may need to use glucocorticoids (prednisone) intermittently and/or intercurrently for the treatment of acute flare-ups.

At the present time, the cox-2 inhibitor celecoxib (Celebrex) is available, although questions have been raised about its safety as well, especially in patients at high risk of cardiovascular complications. Presently, safety and pharmacokinetic data are available for celecoxib in the pediatric population



(Stempak et al., 2002). While this medication is being used anecdotally and compassionately in patients with juvenile rheumatoid arthritis, the only published study on the use of celecoxib in children is in the field of pediatric oncology. The investigators studied the metabolism of celecoxib as part of an ongoing clinical trial evaluating the use of high dose celecoxib in conjunction with other chemotherapeutic agents for anti-angiogenic treatment in children with recurrent solid tumors. Because children differ from adults with respect to drug metabolism, one objective of the study was to determine the single-dose and steady-state pharmacokinetics as well as the safety of anti-angiogenic doses of celecoxib in pediatric patients with solid tumors. The medication was studied in 11 pediatric patients between the ages of six and 16 years of age. Children with various recurrent solid tumors (and one with refractory leukemia) were studied. The observations confirmed the overall safety of the high-dose anti-angiogenic celecoxib (Celebrex) regimen in children and showed a faster clearance and shorter half-life of celecoxib in the pediatric population when compared with adults. This indicated that higher doses and/or more frequent administration may be necessary in the pediatric population compared to the high-dose anti-angiogenic regimen used in adults. Recent data strongly suggest that high-fat foods such as peanut butter taken with the medication may increase plasma concentrations of the celecoxib without increasing the dose of the medication (Stempak et al., 2002).

Celecoxib was extremely well-tolerated by the children in the oncology study despite the fact that they were receiving doses that were significantly higher than those used in adults for the treatment of rheumatoid arthritis or osteoarthritis. The children tolerated drug administration for extended periods of time (as long as 16 months in some cases) without the occurrence of any adverse events. No patient had to be removed from the study for celecoxib-associated toxicity. The authors concluded that celecoxib was well-tolerated by children and appeared to be safe for long-term administration, although the size of the study was small.

Cox-2 inhibitors are still available by prescription. They are currently being tested in children with rheumatoid arthritis, and are being used by pediatric specialists for the treatment of solid tumors and severe inflammatory conditions such as FOP where few other treatment options exist. Studies on the NSAIDs and selective cox-2 inhibitors integrate important findings from the FOP laboratory on prostaglandin production, mast cell recruitment, and angiogenic factor release with the pathologic findings of severe inflammatory pre-osseous lesions of FOP. As with any condition, the relative risks and benefits of potential therapies must be weighed against the potential risks of the underlying condition being treated.

Finally, with all of the existing controversy still swirling around the selective cox-2 inhibitors, the standard NSAIDs, which inhibit both cox-1 and cox-2 non-selectively, are still available and remain an important option to consider as maintenance medications in children and adults with FOP (Table 1). As with the chronic use of all NSAIDs, the risks of serious gastrointestinal side-effects, especially gastrointestinal bleeding, are possible, and special precautions may be warranted in susceptible individuals.

### **E. Aminobisphosphonates**

Bisphosphonates are a potent class of medications that have profound effects on bone remodeling and exert their primary effect by decreasing the life span of osteoclasts. Bisphosphonates are thus widely used in the treatment of numerous bone diseases where bone resorption exceeds bone formation -- disorders such as osteoporosis, osteogenesis imperfecta, Paget's disease, fibrous dysplasia, and bone cancer (Orcel & Beaudreuil, 2002).

The first clinically used bisphosphonate, Etidronate, when administered at high doses, also potentially inhibits mineralization of newly formed cartilage and bone protein and had been proposed as a possible treatment for FOP and other disorders of heterotopic ossification as far back as 35 years ago. Etidronate has been studied in FOP because of its inhibitory effect on bone mineralization and its potential to impair ossification at high dosages. Unfortunately, at high doses, it also causes osteomalacia (soft bones) and impairs ossification of the entire skeletal system, not just the heterotopic bone of the “second skeleton.” Its utility is therefore limited.

The effects of intravenously administered Etidronate and oral corticosteroids were evaluated (Brantus & Meunier, 1998). Thirty-one FOP flare-ups were observed in seven patients during a mean follow-up of six years. In 29 flare-ups, the authors observed a rapid diminution of local inflammation, swelling, and pain during the first seven days of treatment. However, despite Etidronate treatment, ten new ossifications were observed, causing severe deterioration of joint mobility in all affected patients. In 21 flare-ups, no new ectopic ossification appeared. The radiologic pattern of pre-existing ossifications did not change during the treatment. The results suggest the possibility that administration of intravenous Etidronate and oral corticosteroids may be helpful, but more control data on the spontaneous resolution of early flare-ups are needed. While high-dose Etidronate has proven effects on inhibiting mineralization, the newer bisphosphonates do not possess this activity. At the present time, we do not use Etidronate routinely for the treatment of FOP.

While its effectiveness in FOP is uncertain, Etidronate has enjoyed limited use in the treatment of more focal disorders of heterotopic ossification such as those that arise following soft tissue trauma or injuries to the central nervous system. Unlike Etidronate, the newer aminobisphosphonates have no appreciable effect on inhibiting mineralization at doses which are hundreds to thousands of times more potent than Etidronate in inhibiting bone resorption. This property is the basis for the clinical success of aminobisphosphonates in a wide range of bone diseases characterized by excessive bone resorption (Brumsen et al., 1997; Body, 2001; Green, 2002; Still et al., 2003; Black et al., 2007).

So, why would the newer aminobisphosphonates, which act primarily to inhibit bone resorption, even be considered for use in FOP, a condition in which resorption of the heterotopic skeleton would be highly desirable? Not infrequently, an unintended or unexpected use for an old medication is discovered serendipitously in the course of clinical practice.

Several credible and anecdotal reports (to FSK) from physicians and FOP patients worldwide highlighted the response of FOP flare-ups to Pamidronate. One of these reports carefully documented clinical observations on the use of Pamidronate in FOP flare-ups. But, why would Pamidronate even be considered for the treatment of FOP flare-ups? Ironically, in all three cases reported to us, the medication had been used with the mistaken belief that Pamidronate was more potent than Etidronate in inhibiting mineralization. It is not. None of the aminobisphosphonates including Pamidronate have any effect on inhibiting mineralization. Nevertheless, all three patients and their physicians independently reported substantially decreased swelling, redness, and pain following intravenous Pamidronate administration during a new flare-up. In one patient, the Pamidronate was administered alone, while in the other two patients, it was administered along with an oral steroid (such as Prednisone) for several days during the early phases of a new FOP flare-up.

In 2005, Schuetz and colleagues reported generally beneficial anecdotal effects of high-dose aminobisphosphonates in preventing recurrence of heterotopic ossification in high-risk patients with established heterotopic ossification who were undergoing surgery to excise heterotopic bone. One of the five patients reported had FOP. The authors note that the conclusions are preliminary (Schuetz et al., 2005).

All of us in the FOP community know that such anecdotal observations could be purely coincidental - that is, that the flare-ups might have receded spontaneously without treatment and that the Pamidronate might have had nothing to do whatsoever with the reported improvement, especially since oral glucocorticoids were used intercurrently in two of the three FOP patients. Also, one cannot discount a potent placebo effect in any uncontrolled observation. Nevertheless, we also know that such observations of potential improvement in an FOP flare-up cannot be ignored. It is entirely possible to stumble on something worthwhile even for the wrong reason!

As word of this Pamidronate-associated response (with or without steroids) spread rapidly throughout the FOP community, more than a dozen patients (in consultation with us and their local physicians), have used Pamidronate empirically (either alone or with steroids) for the treatment of acute flare-ups, especially those involving major joints. In 10 of the 13 patients (77%), there was reported improvement in the symptoms and signs of an FOP flare-up. In three of the 13 patients (23%), there was no reported improvement in the symptoms or signs of the flare-up by either the physician or the patient. Interestingly, there seemed to be no protective effect whatsoever on the occurrence of subsequent flare-ups in any of the patients treated with either a single dose or a brief course of intravenous Pamidronate. Therefore, whatever improvement there may have been was transient and affected only the lesion present at the time of the flare-up. While these patient reports are not scientifically valid, they constitute an important set of anecdotal observations that compel further stringent scientific inquiry in controlled laboratory and clinical studies.

The treatment protocols varied slightly between the patients (depending on age, body weight, and site of involvement) but in general were similar. The most commonly used protocol is summarized in Section V/Classes of Medications (Table 1). In all patients, serum calcium was monitored prior to treatment to assure that it was in the normal range, as hypocalcemia is a contraindication to the use of intravenous Pamidronate or any of the aminobisphosphonates (Rosen & Brown, 2003). All patients had adequate daily oral calcium and vitamin D supplementation during and following treatment. A serum calcium, phosphate, albumin, alkaline phosphatase, 25-Hydroxy vitamin D, BUN, creatinine and complete blood count (CBC) should also be obtained at baseline. If Pamidronate is used to treat an FOP patient, we recommend that plain radiographs of the affected area should be obtained prior to treatment and six weeks thereafter to document the formation of any heterotopic ossification.

Treatment schedules were based upon published guidelines for children and adolescents with osteogenesis imperfecta as that group constitutes the largest known group of children and adolescents in whom intravenous Pamidronate has been used (Rauch et al., 2002; Falk et al., 2003; Rauch et al., 2003; DiMeglio & Peacock 2006). Patients between two and three years of age received Pamidronate at a dose of 0.75 mg/kg/day for three consecutive days by slow intravenous infusion over 4-5 hours each day. Patients over the age of three years received Pamidronate at a dose of 1.0 mg/kg/day for three days by slow intravenous infusion over 4-5 hours each day, with a maximal dose of 60 mgs/daily. On the first day of the first cycle of treatment, the patient receives half the dose. Lower total doses of Pamidronate ( $\frac{1}{2}$  listed dose on days 2 and 3) and substantially longer durations of infusions (8-10 hours) have been reported anecdotally and have been well-tolerated. The three-day cycle of treatment should be repeated only during flare-ups and no more than 4 times annually. Pamidronate should be administered as early following the appearance of the flare-up as possible and preferably within the first 48 hours. Pamidronate should be diluted in normal saline according to the following table (Guidelines courtesy of F.H. Glorieux: Shriners' Hospital for Children, Montreal):

<b>mg of Pamidronate</b>	<b>ml of Normal Saline</b>	<b>ml/hour</b>
0-5	50	15
5.1-10	100	30
10.1-15	150	45
15.1-25	250	75
25.1-50	500	150
50.1-60	600	180

The maximal concentration of Pamidronate should be 0.1 mg/ml. The IV tubing should be flushed at the end of the infusion to ensure full dose delivery.

Oral corticosteroids (prednisone) can be added to the treatment regimen according to the guidelines listed (Table 1). In general, oral corticosteroids are administered concurrently for 4-5 days for the treatment of flare-ups involving major peripheral joints, the jaw, or the submandibular region. Corticosteroids are generally not used in conjunction with Pamidronate for flare-ups involving the neck, back, or chest as the timing of the onset of flare-ups in those areas is generally more difficult to determine and the reported success of prednisone for flare-ups in those regions has been more equivocal than for flare-ups in the major peripheral joints. The combined use of prednisone and Pamidronate for flare-ups in the trunk and back has therefore not been systemically assessed.

For treatment of acute flare-ups involving major peripheral joints, we do not recommend the use of bisphosphonates alone. Consider a 4-day course of oral prednisone. If swelling recurs following the discontinuation of prednisone, a second 4-day course of high dose prednisone may be given with a slow taper of the prednisone over the following 10 days, in conjunction with a 3-day cycle of IV Pamidronate. In patients who have had multiple steroid courses over the preceding 12 months, the use of Pamidronate or Zoledronate should be considered to reduce bone loss in the normotopic skeleton.

Side-effects of intravenous Pamidronate infusions in FOP patients included flu-like symptoms of fever, chills, and muscle aches. These symptoms can often be lessened by pre-treatment with acetaminophen. One patient developed tetany (uncontrolled muscle contractions due to a low vitamin D level in the blood prior to ameliorative therapy with Pamidronate), and one patient developed peripheral phlebitis (inflammation of the vein) at the intravenous infusion site, which required inpatient intravenous antibiotic treatment. A recently published case report documents the development of iatrogenic osteopetrosis in a child treated with 60 mgs. of intravenous Pamidronate every three weeks for two years. The child did not have FOP and the cumulative doses reported far exceeded any published recommendations for the use of Pamidronate in skeletal diseases (Whyte et al., 2003; Marini, 2003).

Two important cautionary notes about the bisphosphonates are necessary; osteonecrosis of the jaw (ONJ) and low-energy femoral fractures:

Osteonecrosis of the jaw (ONJ) has been increasingly suspected to be a complication of bisphosphonate therapy, especially recurrent intravenous administration of the more potent aminobisphosphonates, such as Pamidronate and Zoledronate (Bilezikian, 2006; Khosla et al., 2007). ONJ, a rare dental condition, is diagnosed when an area of exposed jaw bone shows no sign of healing eight weeks after an invasive

dental procedure, such as a tooth extraction. The gum that would normally cover the bone becomes atrophic, and the underlying jawbone is exposed. Some ONJ patients experience discomfort in the affected part of the mouth. Antibiotics have been effective for some patients, but generally there is no effective treatment and, as in FOP, surgical manipulation of the affected site may exacerbate the underlying condition and should usually be undertaken only by practitioners familiar with ONJ. Clinicians and patients should be aware of this potential complication and a patient's dentist should be made aware of any history of using bisphosphonate medications. Should people taking bisphosphonates for FOP be concerned? Perhaps, but bisphosphonates are used to treat millions of people, and only an exceedingly small number of patients have developed ONJ. However, a small risk is present, and a few precautions are recommended: a dental exam, if possible, before Pamidronate treatment should be considered. Pamidronate should be avoided, if possible within 8 weeks of major dental surgery.

Long-term bisphosphonate use has recently been associated with bilateral low-energy simultaneous or sequential femoral fractures. While the complication is seen in adults only and is very rare, it must be noted. Presently, its significance in FOP patients using intermittent chronic bisphosphonates is unknown (Capeci et al; Black et al., 2010; Shane, 2010), and its overall significance is controversial (Black DM et al., 2010).

Insight and support for the use of Pamidronate in FOP were provided recently by a study in children and adolescents with OI. Treatment with cyclical intravenous Pamidronate infusions (3-4 cycles annually) has led to substantial improvements in the clinical management of children and adolescents with OI, with generalized increases in bone density and dramatically fewer resultant fractures throughout the skeleton. Despite its well-known beneficial effects on skeletal remodeling and bone strength, the effects of Pamidronate on the new endochondral skeletogenesis of the type that would occur at a fracture site, have not been well characterized.

In an extensive study, Dr. Francis Glorieux and colleagues at the Shriners' Hospital for Children and McGill University in Montreal showed that incomplete fracture healing in patients with OI was more than twice as frequent when Pamidronate therapy had been started before the fracture occurred. Furthermore, delayed osteotomy healing was almost four times more frequent when Pamidronate had been started before surgery. The study demonstrated the cyclical intravenous Pamidronate therapy was associated with a significant delay in osteotomy healing in children and adolescents with OI. Although the study was conducted for entirely different reasons and in a different patient population than FOP, the study provides support for the hypothesis that Pamidronate can increase bone density and decrease fracture incidence in the normotopic skeleton through its effect on bone remodeling, while simultaneously inhibiting endochondral skeletogenesis at orthotopic sites (Munns et al., 2004). It remains to be seen, in FOP and in appropriate animal models of BMP-induced heterotopic ossification, whether cyclical infusions of Pamidronate or the more potent aminobisphosphonate zoledronic acid (Zoledronate) can impair endochondral skeletogenesis at heterotopic sites.

Apart from their postulated and observed effect on endochondral skeletogenesis, the use of the aminobisphosphonates could be considered in any FOP patient who is treated intermittently with high dose glucocorticoids for new FOP flare-ups. The aminobisphosphonates generally have an excellent safety and efficacy profile in protecting the normotopic skeleton from the profound osteopenic effects of intermittent high-dose glucocorticoids in the type of regimen that is frequently used to manage acute flare-ups of FOP (Nogginuera et al., 2003; Sambrook et al., 2003; Staa & Cooper, 2003).

An important question that observations from routine clinical care of FOP patients raises is: What might be the physiologic basis for any potential beneficial effect of aminobisphosphonates in the treatment of FOP flare-ups? As a consequence of their potent inhibition of bone resorption, the aminobisphosphonates

effectively inhibit the release of growth factors and morphogens (such as BMPs) which are stored in the extracellular bone matrix of the skeleton. The action of the bisphosphonates on the suppression of bone resorption is exceedingly long, longer than for any other class of medications, and on the order of months to years. Therefore, if aminobisphosphonates inhibited FOP lesions by decreasing the release of BMPs sequestered in the skeleton, one would expect a more pronounced effect on the prevention of subsequent flare-ups than was seen in the patients treated. Clearly, if the aminobisphosphonates are truly beneficial in the treatment of FOP flare-ups, there must be a mechanism of action that is very brief and substantially different from that of osteoclast inhibition from which the medication derives its beneficial effects in the normotopic skeleton.

If bisphosphonates are sequestered at sites of early FOP flare-ups as suggested by radionuclide bone scans, the bisphosphonates would be biologically available to a wide variety of endocytic target cells (monocytes, macrophages, fibroproliferative cells, and angiogenic cells) that compose the early stages of an FOP lesion. Once internalized by a target cell (not yet determined for FOP lesional cells), Pamidronate will disrupt the mevalonate pathway by specifically inhibiting the activity of the farnesyl diphosphate synthase enzyme within the cell. As a result of this enzymatic inhibition, the target cell is rendered incapable of post-translational prenylation of small GTPases such as Ras, Raf, and Rac which are essential for cellular activity. Consequently, target cells are rendered functionally inactive and undergo apoptotic cell death. (Pecherstorfer et al., 2000; Dunford et al., 2001).

One intriguing line of investigation concerns the role of inflammatory cells in triggering heterotopic ossification. Both a genetic approach and a pharmacologic approach were used. Using both approaches, Kan and colleagues showed that monocytes played an important role in the triggering process. Further, Kan and colleagues showed that systemically delivered bisphosphonates powerfully and specifically inhibited monocytes and led to substantial inhibition of trauma-induced heterotopic ossification in a BMP4-transgenic mouse model of heterotopic ossification (Hiraoka et al., 2008; Kan et al., 2009).

While the potential mechanism of action of the aminobisphosphonates on early FOP lesions or BMP-induced FOP-like lesions remains speculative, several recent papers provide some additional clues. These papers, published in the peer-reviewed cancer literature, document the potent antiangiogenic effects of Pamidronate and zoledronic acid *in vitro* and *in vivo*. Also, Pamidronate administered intravenously was shown to dramatically decrease serum vascular endothelial growth factor (VEGF) levels and basic fibroblast growth factor (bFGF) levels in cancer patients with bone metastasis. Both VEGF and basic FGF are potent tumor-associated angiogenesis factors (Fournier et al., 2002; Santini et al., 2002; Wood et al., 2002). More recently, compelling evidence has emerged that zoledronate inhibits endothelial cell adhesion, migration and survival through suppression of multiple prenylation-dependent signaling pathways (Hasmim et al., 2007). Other independent studies have shown that zoledronate has potent anti-angiogenic properties by inhibiting endothelial cell differentiation (Yamada et al., 2009). Taken together, these data strongly suggest that the aminobisphosphonates may be potent anti-angiogenic agents.

The powerful anti-angiogenic effect of some aminobisphosphonates has been demonstrated in mice and may explain the beneficial adjuvant effects of these medications in the treatment of various cancers. The short circulatory half-life of aminobisphosphonates could explain why these medications could benefit active flare-ups when administered early but are unable to prevent future flare-ups.

Intravenous aminobisphosphonates have also been shown to modulate macrophages and various lymphocyte subpopulations in the circulation and may be responsible for its dose-related side-effects of causing flu-like symptoms. We cannot yet rule-out the possibility that Pamidronate may affect early lymphocytic and monocytic infiltration into skeletal muscle seen in both BMP4-induced FOP-like lesions and in FOP lesions themselves. It is also likely that the aminobisphosphonates directly inhibit the

metabolic activity of monocytes and macrophages that play such key roles in the response of the innate immune system to soft tissue injury (Perchersturfer et al., 2000; Dunford et al., 2001).

Other possible mechanisms by which the aminobisphosphonates might affect FOP lesions include a direct inhibition on the proliferation of a rapidly dividing population of cells. Such an effect was noted in studies investigating the effects of aminobisphosphonates on cancer cells *in vitro*. (Tassone et al., 2000; Green, 2003). It is possible that Pamidronate and Zoledronate may affect one or more cell types in an early FOP lesion. Another study showed recently (Idris et al., 2008) that aminobisphosphonates cause osteoblast apoptosis and inhibit bone nodule formation *in vitro*, thus suggesting that aminobisphosphonates may have a direct effect on inhibiting osteoblastic ability, especially in early bone nodules, as in FOP.

Finally, one must consider the stark possibility that there may be no positive effects whatsoever of the aminobisphosphonates on FOP lesions and that the reports to date are the results of observational bias and/or coincidence. Only rigorous controlled investigations *in vitro* and *in vivo*, as well as placebo-controlled clinical trials will be able to definitively decipher these possibilities and provide a solid rational basis for determining whether or not one or more of the aminobisphosphonates may have a beneficial role in the treatment of FOP.

Will Pamidronate and the newer generation of aminobisphosphonates be a goldmine for FOP therapy or will it simply be fool's gold? Only time and rigorous experimental approaches will provide clear answers to that question. While BMP receptor antagonists and BMP pathway signal transduction inhibitors may eventually be definitive in the treatment and prevention of FOP, we hope that the use of more immediately available medications such as glucocorticoids, leukotriene inhibitors, mast cell inhibitors, cox-2 inhibitors, and perhaps the aminobisphosphonates will allow us to buy time for FOP patients. As Jeri Licht, the mother of Daniel Licht stated so eloquently and passionately in the **BBC** documentary, *The Skeleton Key*, "They need to slow down the progression of this condition and slow down or stop the formation of the bone once the flare-up starts. Then they'll have the time, and we'll have the luxury to have them look for a cure for the condition completely."

## **F. Acute & Chronic Pain Management in FOP**

There are many causes of acute and chronic pain in FOP, and each individual must be carefully evaluated before effective treatment can be planned and implemented (Kaplan et al., 2008). Many FOP flare-ups, especially those around the hips and knees, are extremely painful and may require a brief course of well-monitored narcotic analgesia in addition to the use of non-steroidal anti-inflammatory medications, cox-2 inhibitors, and/or oral or IV glucocorticoids. Other types of transient pain syndromes may be caused by neuropathies resulting from acute flare-ups, transient bursitis, inflammation of osteochondromas, arthritis and muscle fatigue, to mention only a few. Most individuals with FOP are pain-free between flare-ups and require little or no chronic analgesia. A small percentage of patients with advanced FOP suffer from generalized chronic pain of diffuse musculoskeletal origin and may require more specialized pain management programs directed by pain management specialists. Attempts should be made to minimize chronic discomfort, and maximize physical and cognitive function. In most cases, narcotic agents should be avoided to minimize the risk of dependency on these agents. While some may require chronic narcotic analgesics late in the course of their disease process, attempts should be made to monitor this carefully to avoid constipation and respiratory suppression. For those with more chronic pain management issues, a consultation with a pain management specialist may be helpful and is recommended.

## **G. Muscle Relaxants**

The concept of using muscle relaxants during acute flare-ups has enjoyed recent popularity among clinicians treating FOP patients (Glaser & Kaplan, 2005). Early FOP flare-ups are associated with intense mast cell, macrophage, and lymphocytic infiltration into skeletal muscle and are often accompanied by intense inflammatory changes within regions of locally damaged or necrotic skeletal muscle. Areas of relatively healthy skeletal muscle bordering the lesion are thus subject to metabolic changes that would lead to muscle spasm and fiber shortening. The judicious short-term use of muscle relaxants such as cyclobenzaprine (Flexeril), metaxalone (Skelaxin), or liorisa (Baclofen) may help to decrease muscle spasm and maintain more functional activity even in the setting of an evolving FOP lesion. This is especially true for painful flare-ups involving the major muscle groups of the back and limbs. The chronic use of muscle relaxants between episodes of flare-ups has not been as widely reported to us by colleagues treating patients with FOP. As with all such medications, careful attention to dosing schedules is important, as certain muscle relaxants (such as liorisa) need to be tapered slowly to avoid side-effects.

## **H. Chemotherapy Agents & Radiation Therapy**

The definitive diagnosis of FOP is often delayed due to the rarity of the condition and the failure to associate the tumor-like soft tissue swellings with the congenital malformations of the great toes. As a result, many children with FOP are misdiagnosed as having a wide range of benign or malignant conditions. It is not surprising, therefore, that many children with FOP have been treated with unnecessary chemotherapy, dangerous surgical excisions, and damaging radiotherapy before the definitive diagnosis of FOP has been made. It would be important to note retrospectively if radiation therapy or any of the chemotherapy agents had been helpful in altering the natural history of the condition. There has been no convincing anecdotal evidence that either radiation therapy or any of the standard chemotherapy agents such as actinomycin, vincristine, vinblastine, cyclophosphamide, doxorubicin, ifosfamide, adriamycin, or any others were helpful for patients with FOP. In fact, many of these medications caused harmful long-term side-effects. The use of these approaches is, therefore, contraindicated in the treatment of FOP (Glaser & Kaplan, 2005; Kaplan et al., 2008). There is, however, one case report in the literature that documents apparently successful treatment of FOP with surgical excision of heterotopic bone, indomethacin, and irradiation. Follow-up was brief (Benetos et al., 2006). At the present time, this approach cannot be endorsed.

## **I. Bone Marrow Transplantation**

A recently published study documented the role of hematopoietic stem cells in FOP. Bone marrow derived stem cells have been implicated in the ectopic bone formation of FOP (reviewed in Kaplan et al., 2007). The replacement of these stem cells by bone marrow transplantation has been suggested as a possible cure for FOP. However, the definitive contribution of bone marrow derived stem cells to the formation of heterotopic bone has remained obscure. Careful clinical observations were made of an FOP patient who underwent bone marrow transplantation twenty-five years earlier for the treatment of intercurrent aplastic anemia. We found that replacement of the FOP patient's bone marrow with normal donor bone marrow cured his fatal bone marrow condition but was not sufficient to prevent further heterotopic ossification and progression of his FOP. However, acute immunoablation and chronic immunosuppression quenched the activity of his FOP.

In complementary transplantation studies in mice, we found that blood cells derived from the bone marrow contributed to the early inflammatory and to the late marrow repopulating stages of BMP4-



induced bone formation, but were not present in the fibroproliferative, chondrogenic or osteogenic stages of the FOP-like lesions (Kaplan et al., 2007).

Taken together, these findings demonstrated that bone marrow transplantation did not cure FOP in this patient, most likely because the blood-making stem cells from the bone marrow were not the source of cells that formed the FOP lesions. However, even normal bone marrow-derived cells were capable of stimulating heterotopic ossification in a genetically susceptible individual (Kaplan et al., 2007).

These findings are of immense research interest and vital clinical importance, and they exemplify powerfully how much can be learned by careful observation in an individual patient. They also illustrate the importance of the immune system in triggering FOP flare-ups. At present, however, the general use of potent immunosuppressive medications is not advocated in the routine management of FOP, and would likely be extremely dangerous and possibly life-threatening if it were applied broadly to the FOP community. At the present time, (and until further studies are performed in appropriate animal models), this international consortium recommends against the use of chronic immunosuppressive medications in the management of FOP.

### **J. Rosiglitazone**

The recent discovery of the mutated gene that causes FOP (Shore et al., 2006), an extraordinarily specific mutation in a highly conserved bone morphogenetic protein (BMP) receptor (Shore et al., 2006), immediately predicted the mutant receptor and downstream pathway as an ideal target for drug therapy (Hong & Yu, 2009).

A recent case report by Gatti et al from the University of Verona approaches the problem from a different perspective (Gatti et al., 2010). The report claims that rosiglitazone (Avandia), an anti-inflammatory and anti-diabetic agent that alters the fate of marrow stromal cells, “is associated with major clinical improvements in a patient with fibrodysplasia ossificans progressiva (FOP).” (Gatti et al., 2010) Gatti et al describe a 48 year-old woman with FOP characterized by continuous flares that she was partially controlling with prednisone. She took rosiglitazone (initially 4 mgs, and then 8 mgs daily) for 14 months. No new flares were observed during rosiglitazone therapy, as compared to five episodes observed during the previous year while on 20-25 mgs of prednisone daily. “The steroid dose was progressively lowered to 5 mgs daily, the skin became softer and the articular mobility impressively improved,” according to the authors who concluded that “rosiglitazone therapy, possibly in association with small doses of prednisone, is associated with important clinical improvements in patients with FOP.” (Gatti et al., 2010).

Rosiglitazone is an anti-diabetic drug, useful for the treatment of type-2 diabetes (Oakes et al., 1994). In addition, it appears to have a potent anti-inflammatory effect as well as an adverse effect on the skeleton (McDonough et al., 2008; Meier et al., 2008). The authors postulate that the adverse skeletal effects might be exploited therapeutically in diseases like FOP (Gatti et al., 2010).

In 2005, major safety concerns emerged about the use of rosiglitazone:

1. Rosiglitazone has adverse cardiovascular side effects including an increased risk of heart attacks and death from all cardiovascular causes (Nissen et al., 2007).

2. Rosiglitazone causes osteoporosis and decreased skeletal strength that is reminiscent of aged bone (McDonough et al., 2008). Pathologic fractures of long bones occur with chronic rosiglitazone use (Meier et al., 2008).
3. Rosiglitazone is not approved for use in children.

There are concerns about the interpretation of data in the case report by Gatti et al. Specifically:

1. The authors conclude that “rosiglitazone therapy is associated with important clinical improvements in patients with FOP.” However, the data were for drug treatment in a single patient, not in multiple patients, and there were no controls.
2. “Flare-ups of FOP are sporadic and unpredictable, and there is great individual variability in the rate of disease progression. Several large studies on the natural history of FOP have confirmed that it is impossible to predict the occurrence, duration, or severity of an FOP flare-up.” (Kaplan et al., 2008). Thus, the clinical course of a single individual cannot be used to assess therapeutic efficacy.
3. The rarity of FOP and the unpredictable nature of the condition make it extremely difficult to assess any therapeutic intervention, a fact recognized as early as 1918 by Jules Rosenstirn, who noted: “The disease was attacked with all sorts of remedies and alternatives for faulty metabolism; every one of them with more or less marked success observed solely by its original author, but pronounced a complete failure by every other follower. In many cases, the symptoms of the disease disappear often spontaneously, so the therapeutic effect (of any treatment) should not be unreservedly endorsed.” (Rosenstirn, 1918).
4. Exacerbations and remissions are common in FOP and often occur spontaneously. Almost every adult with FOP has experienced a remission while taking a medication that was later proven useless (Kaplan et al., 2008).
5. It is not possible from the data presented, to separate the effects, if any, of rosiglitazone from those of chronic prednisone use. Although high dose, long-term prednisone use is not recommended for the treatment of FOP, its use in animal models is effective in decreasing heterotopic bone (Kaplan et al., 2008).
6. It is possible that the anti-inflammatory effect of rosiglitazone could have participated in the quiescence of flare-ups noted in this patient. Alternatively, the attributed effect might have been spontaneous and unrelated to the medication, or possibly a delayed effect of the chronic prednisone use (Kaplan et al., 2008).

Despite concerns associated with chronic rosiglitazone use and the biases inherent in the case report, the observation in this single patient is sufficiently interesting to prompt further investigation in emerging animal models of FOP (Shore et al., 2006). Ultimately, these studies must separate the postulated effects of rosiglitazone from the known effects of prednisone. *In vivo* testing of rosiglitazone in animal models of

FOP is necessary to determine if there may be a physiological basis for a limited use in FOP, considering its safety profile.

FOP is a catastrophic disease with unimaginable human suffering. Affected individuals and their families are vulnerable to hype, and are suspicious of inflated claims. In our opinion, rosiglitazone should not be

used in FOP patients without Investigational Review Board approval. At present, we favor *in vivo* studies in emerging animal models of FOP. Extreme caution is necessary until animal testing is completed and it can be determined whether or not there is a physiological basis for rosiglitazone use in treating or preventing FOP flare-ups.

In summary, the key questions remain:

1. Does rosiglitazone reduce or prevent FOP flare-ups?
2. If so, is rosiglitazone safe enough to warrant its chronic use in patients with FOP?

The simple answer to both questions is “perhaps, but we do not know.” It is prudent to get real answers before viewing FOP through Rosi-colored glasses (Kaplan et al., 2010).

### **K. Retinoic Acid Receptor Agonists**

As far back as the 1980s, retinoids, used for the treatment of acne, were known to cause skeletal birth defects if taken during pregnancy because they interfere with the formation of the cartilaginous scaffold on which the embryonic skeleton is built. The idea of using retinoids to treat FOP flare-ups was simple, and elegant: if retinoids caused birth defects by disrupting the formation of the cartilaginous scaffold of the normal skeleton, perhaps they might retard the formation of the cartilaginous scaffold of the heterotopic or second skeleton of FOP.

In the mid-1980s, more than 20 years before the FOP gene was discovered, Dr. Michael Zasloff, then at the National Institutes of Health, conducted a clinical trial of isotretinoin (13-cis-retinoic acid; accutane), a powerful retinoid, for the prevention and treatment of FOP (Zasloff et al., 1998). Although the results of the clinical trial were equivocal and the side effects of high-dose isotretinoin generally intolerable, the idea of using a retinoid to prevent or treat FOP flare-ups was far ahead of its time.

Over the past 30 years, nuclear receptors for retinoids have been discovered, and specific agonists (molecules that activate specific retinoid receptor subtypes) that possess far greater specificity and far fewer side effects than isotretinoin have been developed.

In the April 2011 issue of **Nature Medicine**, Dr. Masahiro Iwamoto (senior author) and his colleagues (Shimono et al., 2011) offer a novel approach to derail heterotopic ossification, not prior to induction, but rather after the process of building a second skeleton has begun. The authors build on previous work that retinoic acid is a potent skeletal teratogen that can be exploited to interfere with the cartilage scaffold of heterotopic endochondral ossification (HEO) before the dreaded endstage of disabling heterotopic ossification is reached.

In their landmark study, the authors show that the early chondrogenic (cartilage producing) stage of the pre-bone scaffold is exquisitely sensitive to the inhibitory effects of retinoic acid receptor gamma (RAR $\gamma$ ). By using compounds that specifically activate the RAR $\gamma$  receptor, the authors are able to critically target and inhibit the pre-cartilage and cartilage cells that follow from the inflammatory start signals and that are used as the scaffold to form mature heterotopic bone (Kaplan & Shore, 2011).

A previous study by the same research group (Shimono et al., 2010) showed that compounds that activate the retinoic acid receptor alpha (RAR $\alpha$ ) inhibit HEO, but do so in an incomplete manner, much like isotretinoin. In contrast, RAR $\gamma$  is more specifically expressed in cells that form the cartilage scaffold.

Therefore, the authors postulated that RAR $\gamma$  agonists might possibly be more effective in inhibiting HEO. In their mouse experiments, the authors employ a comprehensive approach using implanted stem cells, BMP induction of HEO, and a conditional transgenic mouse that forms FOP-like HEO and show that RAR $\gamma$  agonists potently inhibit HEO. Remarkably, when the RAR $\gamma$  agonists are stopped, no significant rebound effect occurs, indicating that the RAR $\gamma$  effect may be irreversible (Shimono et al., 2011; Kaplan & Shore, 2011).

Importantly, the authors show that this class of compounds is effective in inhibiting HEO in animal models during a wide treatment window that includes the pre-cartilage mesenchymal stem cell phase, up to, but not including, the bone formation phase. These tantalizing findings suggest that the successful inhibition of HEO in patients may be possible even after the clinically elusive induction phase has occurred (Shimono et al., 2011; Kaplan & Shore, 2011).

Most remarkably, the authors show that this class of compounds may actually redirect cell fate decisions in mesenchymal stem cells to a non-bone lineage, an observation with wide-reaching implications for skeletal oncology, vascular biology, and tissue engineering. Thus, the RAR $\gamma$  agonists may prevent HEO by two distinct cellular mechanisms: sabotaging pre-cartilaginous and cartilaginous scaffold formation once the train has reached the bridge, and/or backing-up the train to the station before it has reached the bridge.

Taken together, the authors provide a tour-de-force in identifying a potent, orally available class of compounds that can prevent HEO in animal models by inhibiting the cartilage scaffold, and by diverting stem cells to a more benign soft tissue fate while avoiding the rebound phenomena seen in other classes of experimental medications (Shimono et al., 2011; Kaplan & Shore, 2011).

The authors' remarkable findings raise intriguing questions. Most importantly, given that the formation of heterotopic bone requires participation of the BMP signaling pathway, how might RAR $\gamma$  agonist compounds impair HEO from a constitutively active BMP type I receptor as in FOP, or in the FOP-like transgenic mouse model in which the constitutively active ACVR1/ALK2 receptor is conditionally activated by inflammation? The answer lies, at least in part, with an unusual mechanism of action. The authors show that the RAR $\gamma$  agonists dramatically and irreversibly downregulate BMP signaling by promoting the degradation of molecules in the molecular relay race immediately downstream of the overactive FOP receptor. These activated molecules, called "phosphorylated BMP-pathway specific Smads," are thus blocked from entering the nucleus of the mesenchymal stem cells and early cartilage cells, and thus prevented from activating heterotopic ossification. Dr. Pacifici and his colleagues also speculate that another important signaling pathway called the Wnt/ $\beta$ -catenin signaling pathway, known to inhibit cartilage formation, is activated by these compounds. Thus, the RAR $\gamma$  agonists likely block the cartilaginous scaffold of heterotopic ossification in an encompassing manner by both inhibiting BMP signaling (that is overactive in FOP) and stimulating the Wnt/ $\beta$ -catenin signaling pathway (that is inhibitory) (Shimono et al., 2011; Kaplan & Shore, 2011).

The therapeutic implications of this work for preventing HEO in common, sporadic forms of the condition and in FOP are enormous, but some clinical caveats remain. First, RAR $\gamma$  agonists, like the earlier molecules used, cause birth defects and their use in woman of childbearing age must be monitored carefully. Second, the authors predictably show that RAR $\gamma$  agonists delay endochondral bone formation during fracture repair. Thus, these agents may have limited applicability in patients with long bone fractures in addition to their heterotopic ossification-prone injuries (such as wounded soldiers and civilians with multiple traumatic injuries). Third, long term use of these compounds may adversely affect the cartilaginous growth plates, and additional studies in knock-in mice with the classic FOP mutation are

necessary before RAR $\gamma$  agonists can be considered for long-term use in children. Nevertheless, RAR $\gamma$  agonists are presently in clinical trials for other disorders, likely expediting their application to FOP and other HEO conditions (Shimono et al., 2011; Kaplan & Shore, 2011).

It is difficult to find effective molecular targets for intractable diseases. Successful therapeutic sabotage of highly conserved signaling pathways, as in FOP, requires exquisite planning and good fortune. Shimono et al. combine both in their elegant study. They identify RAR $\gamma$  agonists as a class of compounds that profoundly inhibit the BMP-induced cartilage scaffold of FOP. The beauty of this approach is that it does not just broadly target the BMP signaling pathway in many tissues in the body, but rather it targets a specific pathological process of tissue metamorphosis (cartilaginous scaffold formation) that requires the BMP signaling pathway to cause disabling disease. Thus, it has the desired features of targeting the molecular basis for FOP in the very cells that cause HEO, hopefully with minimal collateral damage. The authors have thus identified a new and powerful class of compounds to derail the cartilaginous scaffold of HEO in FOP. Without the cartilage scaffold, there is no HEO in FOP. With some additional work, these compounds seem RARing to go in clinical trials for FOP patients and others, who are desperately waiting for clinical answers (Kaplan & Shore, 2011).

### **L. Miscellaneous Agents**

The chronic use of calcium binders, mineralization inhibitors, antiangiogenic agents, fluoroquinolone antibiotics, PPAR-gamma agonists, colchicine, and warfarin have been reported with either unsatisfactory or equivocal results. At the present time, the use of these medications or approaches can not be endorsed (Moore et al., 1986; Wieder, 1992; Gatti et al., 2009; Kaplan et al., 2009). TNF-alpha inhibitors might theoretically provide some benefit (Olsen & Stein, 2004). Recently, there have been some anecdotal reports on the use of TNF-alpha inhibitors, but data are scant and no published series are available. While there has been one case report of successful surgical excision of heterotopic bone in a patient with FOP, such an approach is not recommended, as the literature is littered with casualties following similar adventures (Benetos et al., 2006).

### **M. Targeting ACVR1/ALK2: Definitive Targets for Therapy**

*“With so much being discovered about how the BMPs act, it might be possible to develop drugs that would block some part of the BMP pathway and therefore prevent the progression of what is a horrible, nightmare disease.”*

- Brigid Hogan (Roush, 1996)

The ultimate goal of FOP research is the development of treatments that will prevent, halt, or even reverse the progression of the condition. The prevention and treatment of heterotopic ossification in FOP, as in any of the more common forms of heterotopic ossification, will ultimately be based on at least one of four approaches: disrupting the inductive signaling pathways, suppressing the inflammatory triggers, altering the relevant osteoprogenitor cells in the target tissues, and/or modifying the tissue environment so that it is less conducive to heterotopic osteogenesis.

The identification of the recurrent heterozygous missense point mutation that causes FOP in all classically affected individuals provides a specific pharmaceutical target and a rational point of intervention in a critical signaling pathway. The discovery of the FOP gene identifies ACVR1/ALK2 as a susceptible

pharmaceutical target for the treatment of FOP. Plausible therapeutic strategies to inhibiting BMP signaling in FOP include inhibitory RNA technology, monoclonal antibodies directed against ACVR1/ALK2, orally available small molecule selective signal transduction inhibitors (STIs) of ACVR1/ALK2 (Shore et al., 2006; Kaplan, 2006; Fukada et al., 2007; Kaplan et al., 2007; Shen et al., 2007; Kaplan et al., 2008; Yu et al., 2008; Hong et al., 2009; Kaplan et al., 2009), and most recently, retinoic acid receptor gamma (RAR $\gamma$ ) agonists that target ACVR1/ALK2 signaling in the pre-chondrogenic anlagen of heterotopic ossification (Shimono et al., 2011; Kaplan & Shore, 2011).

Recently, Dorsomorphin has been identified as a powerful orally-available signal transduction inhibitor of BMP signaling (Yu et al., 2008). Dorsomorphin and its derivatives are powerful inhibitors of BMP type I receptors in FOP cells (Fukada et al., 2007), and preliminary data suggest that this category of STIs may play a powerful role in inhibiting heterotopic ossification in animal models of promiscuous ACVR1/ALK2 activity (Cuny et al., 2008; Yu et al., 2008; Kaplan et al., 2009). Nevertheless, rebound effects and off-target effects remain a major concern (Hong et al., 2009). Further extensive testing in animal models of true FOP will be necessary to more completely evaluate potential efficacy and safety.

It is still too early to determine which one of these approaches or combinations of approaches will be most effective, and all are being studied intensively in the laboratory. Much of the present worldwide collaborative research effort in FOP is focused on this area of research, and detailed accounts of the work and progress can be found in the Twentieth Annual Report of the FOP Collaborative Research Project (Kaplan, Pignolo, Shore et al., 2011), as well as in recent reviews.

### **III. SPECIAL MEDICAL CONSIDERATIONS**

#### **A. Introduction**

Individuals who have FOP can also develop common problems (gall bladder disease, appendicitis, colds, earaches, etc.) as with anyone in the general population. Generally, the safest way to diagnose and treat these problems in a patient with FOP is to ask the question: “How would I evaluate this patient if he or she did not have FOP?” Following that, the “FOP filter” can be applied to ask: “Given the nature of the possible intercurrent medical problem, and the relative risks that particular problem presents in relation to FOP, are there any diagnostic or treatment procedures that should or should not be undertaken (or perhaps alternative diagnostic procedures might be more appropriate)?” Using that approach, diagnostic dilemmas can often be resolved and appropriate care delivered. When questions remain, experts on FOP should be consulted (Kaplan et al., 2011; see Section X. The International Clinical Consortium on FOP).

In addition to common medical problems that individuals with FOP might have, there are a number of special medical considerations for FOP patients that are worthy of very special attention. They are presented below.

#### **B. Injury Prevention in FOP**

Prevention of soft-tissue injury and muscle damage remain a hallmark of FOP management. Intramuscular injections must be avoided. Routine childhood diphtheria-tetanus-pertussis immunizations administered by intramuscular injection pose a substantial risk of permanent heterotopic ossification at the site of injection, as do arterial punctures whereas measles-mumps-rubella immunizations administered by subcutaneous injection and routine venipuncture pose no significant risk (Lanchoney et al., 1995). Biopsies of FOP lesions are never indicated and may cause additional heterotopic ossification.

Permanent ankylosis of the jaw may be precipitated by minimal soft tissue trauma during routine dental care. Assiduous precautions are necessary in administering dental care to anyone who has FOP. Overstretching of the jaw and intramuscular injections of local anesthetic must be avoided. Mandibular blocks cause muscle trauma that will lead to heterotopic ossification, and local anesthetic drugs are extremely toxic to skeletal muscle (Luchetti et al., 1996).

Falls suffered by FOP patients can lead to severe injuries and flare-ups. Patients with FOP have a self-perpetuating fall cycle. Minor soft tissue trauma often leads to severe exacerbations of FOP, which result in heterotopic ossification and joint ankylosis. Mobility restriction from joint ankylosis severely impairs balancing mechanisms, and causes instability, resulting in more falls (Glaser et al., 1998).

Falls in the FOP population are more likely to result in severe head injuries, loss of consciousness, concussions, and neck and back injuries, compared to people who do not have FOP, due to the inability to use the upper limbs to absorb the impact of a fall and to anatomic abnormalities of the cervical spine in individuals with FOP. FOP patients are much more likely to be admitted to a hospital following a fall and have a permanent change in physical function because of the fall. In a group of 135 FOP patients, 67 percent of the reported falls resulted in a flare-up of the FOP. Use of a helmet by young patients may help reduce the frequency of severe head injuries that can result from falls (Glaser et al., 1998).

Measures to prevent falls should be directed at modification of activity, improvement in household safety, use of ambulatory devices (such as a cane, if possible), and use of protective headgear. Redirection of activity to less physically interactive play may also be helpful. Complete avoidance of high-risk

circumstances may reduce falls, but also may compromise a patient's functional level and independence, and may be unacceptable to many. Adjustments to the living environment to reduce the number of falls within the home may include installing supportive hand-railings on stairs, securing loose carpeting, removing objects from walkways, and eliminating uneven flooring including doorframe thresholds. Prevention of falls due to imbalance begins with stabilization of gait. The use of a cane or stabilizing device may improve balance for many patients. For more mobile individuals, the use of a rolling cane or a walker will assist in stabilization.

When a fall occurs, prompt medical attention should be sought, especially when a head or neck injury is suspected. Any head or neck injury should be considered serious until proven otherwise. A few common signs and symptoms of severe head injury include increasing headache, dizziness, drowsiness, obtundation, weakness, confusion, or loss of consciousness. These symptoms often do not appear until hours after an injury. An FOP patient should be examined carefully by a healthcare professional if a head or neck injury is suspected.

### **C. Spinal Deformity in FOP**

Spinal deformities are common in individuals who have FOP. A study in 40 FOP patients showed that 65 percent had radiographic evidence of scoliosis. The initial clinical abnormality was a rapidly developing scoliosis associated with a spontaneously occurring lesion in the paravertebral soft tissues. Once established, these deformities lead to rapid, permanent loss of mobility and to progressive spinal deformity with growth (Shah et al., 1994).

The formation of a unilateral osseous bridge along the spine prior to skeletal maturity limits growth on the ipsilateral side of the spine while growth continues uninhibited on the contralateral side. If an osseous bridge occurs bilaterally and the two bridges are relatively symmetrical, or if an osseous bridge forms after skeletal maturity, scoliosis will not result.

Severe scoliosis in FOP can lead to pelvic obliquity, similar to that seen in scoliosis resulting from other causes, and the obliquity can impair the balance of the trunk as well as standing and/or sitting balance.

Anecdotal experience in five patients suggests that traditional operative approaches to scoliosis in FOP patients can seriously exacerbate the disease. Furthermore, three patients in the series who had operative correction of the scoliosis continued to have progression of the spinal curve even after a spinal arthrodesis. In two of these patients, the arthrodesis was performed posteriorly and not anteriorly. Thus, continued anterior growth of the spine exacerbated rotational deformity. Indications for correction of spinal deformity associated with more usual types of scoliosis do not pertain to patients with FOP. With the limited knowledge available, the risks of severe complications (most notably, the exacerbation of heterotopic ossification at sites remote from the operative field) that are associated with correction of spinal deformity in FOP likely outweigh the benefits.

A recent study of three patients with rapidly evolving chin-on-chest deformities suggests that a more aggressive surgical approach may be necessary to prevent and/or correct such rapidly progressive deformities in patients who have FOP (Moore et al., 2009).



## **D. Cardiopulmonary Function in FOP**

Patients with FOP develop thoracic insufficiency syndrome (TIS) that can lead to life-threatening complications. Features contributing to TIS in patients with FOP include:

- Costovertebral malformations with orthotopic ankylosis of the costovertebral joints
- Ossification of intercostal muscles, paravertebral muscles and aponeuroses
- Progressive spinal deformity including kyphoscoliosis or thoracic lordosis

Pneumonia and right-sided heart failure are the major life-threatening hazards that result from TIS in patients with FOP. Prophylactic measures to maximize pulmonary function, minimize respiratory compromise, and prevent influenza and pneumonia are helpful in decreasing the morbidity and mortality from TIS in patients with FOP (Kussmaul et al., 1998; Kaplan & Glaser, 2005; Kaplan et al., 2010).

Individuals with FOP develop progressive limitations in chest expansion, resulting in restrictive lung disease, with reduced vital capacity but no obstruction to air flow. Those with advanced disease have extremely limited chest expansion and rely on the diaphragm for inspiration (Kussmaul et al., 1998). The low inspiratory capacity results in low expiratory flow rates, in many cases. Consequently, individuals with FOP are subject to atelectasis, retained secretions, and pneumonia.

The respiratory problems seen in patients with FOP are similar to those seen in patients with respiratory muscle weakness such as cervical spinal cord injury, or other skeletal abnormalities such as kyphoscoliosis. Strategies similar to those used in these other populations to maximize respiratory muscle functional and clear secretions may be beneficial in those with FOP.

Inspiratory and expiratory muscle training should be routinely practiced. A variety of incentive spirometers are available to encourage deep breathing. Inspiratory muscle training devices permit progressive resistance exercise training of the diaphragm.

Careful attention should be directed toward the prevention and therapy of intercurrent chest infections. Such measures should include prophylactic pneumococcal pneumonia and influenza vaccinations (given subcutaneously), chest physiotherapy, and prompt antibiotic treatment of early chest infection. Upper abdominal surgery should be avoided if possible, as it interferes with diaphragmatic respiration. Sleep studies to assess sleep apnea may be helpful, and positive pressure assisted breathing devices such as BiPAP® (Bi-level positive airway pressure) masks without the use of supplemental oxygen may also be helpful.

Patients with FOP who have advanced TIS and who use unmonitored oxygen have a high risk of sudden death. Sudden correction of oxygen tension in the presence of chronic carbon dioxide retention suppresses respiratory drive. Patients who have FOP and severe TIS should not use supplemental oxygen in an unmonitored setting (Kaplan & Glaser, 2005).

There is also much that can be done in prevention. Individuals with FOP are often born with congenital malformations of the costovertebral joints that cause some degree of chest restriction even before the appearance of heterotopic bone, although these restrictions may not lead to any clinical problems early in life. However, because of these restrictions, individuals with FOP are more likely to rely, even early in life, on diaphragmatic breathing. It is recommended that individuals with FOP be evaluated by a pulmonologist by the end of the first decade of life in order to perform baseline pulmonary function tests

and echocardiograms. The results of these tests may further help guide preventative care for the cardiopulmonary system.

During hospitalizations or in more advanced disease, individuals with FOP may have more trouble clearing secretions. This can lead to atelectasis, pneumonia and respiratory failure requiring intubation. Secretion clearance is enhanced by adequate hydration, guaifenesin, and use of bronchodilators and mucolytics, as needed. Several devices are available to loosen secretions from relatively simple handheld devices that cause vibration of the airway walls during exhalation, to garments that vibrate the chest wall to high technology specialty beds that turn and oscillate. Care must be taken when using such devices in patients with a weak cough, as they may be unable to expectorate the secretions once loosened. Use of mechanical insufflation-exsufflation can non-invasively extract retained secretions from individuals with ineffective cough. The device can dramatically increase peak cough expiratory flow in individuals with impaired expiratory muscle function. Combining a method to loosen secretions with in-exsufflation to remove them may prevent respiratory failure and the need for mechanical ventilation.

Various activities can help maximize the strength of the diaphragm and perhaps decrease the risk of intercurrent pulmonary problems. In addition to the intermittent use of incentive spirometry, other activities such as deep breathing, swimming/hydrotherapy, and singing, may help improve long-term pulmonary function.

## **E. Immunizations & FOP**

Influenza & FOP is a dangerous and potentially deadly combination. Influenza causes FOP flare-ups, and influenza can cause potentially deadly cardiopulmonary complications, especially in individuals with severe restrictive chest wall diseases as in FOP.

**1. Influenza.** Flare-ups of FOP are most commonly triggered by soft tissue injury. After observing severe flare-ups of FOP in two half-sisters with culture-confirmed influenza B infections, we hypothesized that influenza-like viral illnesses can also trigger flare-ups of FOP. To address this hypothesis, we designed a questionnaire to assess whether patients with FOP experienced influenza symptoms during an influenza season, and whether these symptoms were correlated with flare-ups of the condition. The questionnaire was sent to patients with FOP worldwide. Of the 264 patients surveyed, 123 (47%) responded. The survey revealed that the risk of a disease flare-up of FOP during an influenza-like viral illness was elevated by at least a factor of three and possibly much more (Scarlett et al., 2004). Thus, patients with FOP have a substantial additional risk of flare-ups from influenza-like viral illnesses. Such flare-ups affect the chest wall and imperil the already precarious respiratory status. Patients with FOP should promptly seek medical attention of influenza-like syndromes (Scarlett et al., 2004).

The survey data strongly supported the hypothesis that influenza-like viral illnesses were associated with disease flare-ups in patients who have FOP. Influenza-like viral illnesses in FOP patients may be a source of previously unrecognized muscle injury leading to heterotopic ossification and permanent loss of mobility. These findings have important implications for understanding and preventing environmental triggers of disease activity in this population of patients genetically susceptible to progressive heterotopic ossification.

Influenza is a dangerous disease even for healthy individuals, and it is even more dangerous for those who have FOP. The United States Center for Disease Control and Prevention in Atlanta estimates 20,000 deaths and 114,000 hospitalizations annually due to complications of influenza. Common complications include severe life-threatening pneumonia as well as severe muscle damage that leads to kidney failure,

requiring dialysis. The greatest risk of complications from flu occurs in infants, the elderly and those who are disabled. Patients who have FOP are particularly susceptible to complications from the flu. This is due to the severe restrictive disease of the chest wall that occurs at an early age and leads to a lifelong increased risk of developing life-threatening complications of respiratory infections.

Patients with FOP should consider receiving influenza immunizations annually. Additionally, unaffected household members of patients with FOP should consider annual immunizations to decrease the risk of spreading the flu to highly susceptible FOP patients.

It is generally recommended that patients who have FOP avoid intramuscular immunizations. A published report which examined different routes of administration of the flu vaccine (in non-FOP patients) suggested that the flu shot can be given subcutaneously and induces similar levels of antibodies against the flu compared to the intramuscular immunization (Halperin et al., 1979).

Shortage of flu vaccine in the United States during the 2004-2005 season prompted several important studies to determine if the flu vaccine was effective at a fraction of its normal strength when administered intradermally (in the skin). Intradermal administration of the influenza vaccine facilitates exposure of influenza-antigens to dendritic cells in the skin that can stimulate the lymph nodes to mount a protective antibody response. As compared with intramuscular immunizations, intradermal immunizations were hypothesized to induce similar antibody responses with a smaller quantity of vaccine (Belshe et al., 2004; Cooper et al., 2004; Kenney et al., 2004; La Montagne & Fauci, 2004; Pearson, 2004).

One study showed that an intradermal injection of a reduced dose of influenza vaccine (as compared with an intramuscular injection of full-dose influenza vaccine), resulted in similarly vigorous antibody responses among persons 18-60 years of age. In two other studies, intradermal administration of one-fifth or one-tenth of the standard intramuscular dose of influenza vaccine elicited an immune response that was similar or better than that elicited by the full dose intramuscular injection. Intradermal administration could therefore be used to expand the recipient population for influenza vaccine, but further studies are needed before the strategy can be recommended for routine use. Nevertheless, the intradermal route of administration, which was explored and studied in an attempt to expand the availability of the vaccine, can cautiously be applied to the FOP patient population who cannot otherwise receive intramuscular injections. The intradermal route of administration bypasses the need to give an intramuscular immunization, and may be as effective. The studies do not prove conclusively that the weaker dose of the vaccine given intradermally prevents active influenza during the flu season as effectively as a normal dose nor do they show what is the best dose for high-risk groups such as young children, the elderly, or those who have FOP. Nevertheless, the published studies offer a possible alternative that could be used compassionately in high-risk populations including FOP patients.

The decision to have a flu shot (as well the route of administration) is a personal decision that must be made by each patient who has FOP in consultation with his/her physician.

The flu vaccine should never be given to someone who is allergic to eggs (since the flu vaccine is developed and cultured in eggs). The flu vaccine should never be given to anyone who has had a previous severe adverse reaction to the influenza vaccine. Most importantly, the flu vaccine should never be given to an FOP patient during the time of an active flare-up. Neuraminidase inhibitors could be considered if influenza develops (Moscona, 2005), but there has been little experience with them in the FOP community.

An intranasal influenza vaccine was approved by the US Food & Drug Administration (FDA) and is now available for administration, where not otherwise contraindicated, in individuals from 5 to 49 years of age

(Belshe et al., 2007). This would circumvent the need for a flu shot of any type and might be an attractive option in some patients who have FOP. The intranasal influenza vaccine is much more expensive than the traditional flu shot, but is readily available. This method of immunization is quite new and uses a live attenuated flu virus. There is also much less experience with the intranasal influenza vaccine in the FOP community. One young child who received the intranasal flu vaccine developed a severe flare-up of FOP two days after receiving the vaccine. This might have been coincidental or might have been due to the live virus vaccine. It is impossible to say. However, several other children with FOP have received the intranasal flu vaccine without any adverse effects. Interestingly, among young children, the intranasal flu vaccine had significantly better efficacy than the inactivated vaccine (Belshe et al., 2007).

Whatever decision is made for a particular individual, it should be made following careful consideration of the FOP patient's past medical history and consultation with his/her local physician. Many patients have strong views about immunizations and there are no easy answers here. It is important to remember, however, that influenza can be an extremely severe and life-threatening disease even in healthy individuals, and even more so in patients who have FOP. Thus, while there are risks of immunization, there are also substantial and life-threatening risks of influenza infection. Many patients incorrectly attribute symptoms of a cold to "influenza." It is important to remember that influenza is a completely different illness than a bad cold, and flu can be a severe life-threatening infection to anyone, especially to young children, to the elderly, and to the disabled.

The recent emergence of the H1N1 influenza (swine flu) has added an increased level of concern regarding patients who have FOP (Hancock et al., 2009; Jain et al., 2009; Monto et al., 2009; Wenzel et al., 2009). It is important to keep in mind that influenza and influenza-like illnesses are caused by viruses and can trigger flare-ups of FOP. As before, it is important to take the usual precautions, as one would in any influenza season. These are well-outlined above. Also, a common sense approach to keeping healthy is important such as avoiding crowds, washing the hands frequently, and avoid touching and rubbing the eyes, nose, and face. In addition to the seasonal influenza, there are additional concerns about the swine flu. As with seasonal influenza immunizations, swine flu should be given to all children including those have FOP and should be administered subcutaneously (under the skin).

Immunizations should be given with the smallest possible needle and always underneath the skin, if possible. If an immunization cannot be given subcutaneously, it should not be administered. Ice should be applied to the immunization site intermittently for 24 hours after an immunization.

As with the seasonal influenza vaccine, the nasal spray vaccine should not be administered to an FOP patient as it is a live attenuated virus and could more easily cause a flare-up.

If someone decides not to receive either a seasonal or swine flu immunization, then they should consider having antiviral medication prescribed by their local doctor in case the flu does occur. Also, it is recommended that any household contact of FOP patients should definitely consider being vaccinated for the regular flu as well as the swine flu.

In 2009, the swine flu vaccine and the seasonal influenza vaccine were produced separately due to the late identification of swine flu as a potential pandemic/epidemic problem. However, in future years, immunization against the swine flu will likely be included in the seasonal influenza vaccine.

The old adage about an ounce of prevention is still true. Common sense old-fashioned methods to decrease the risk of an influenza infection need to be heeded. Avoidance of influenza is a multi-faceted process and includes annual immunizations, as well as common sense methods of prevention.

**2. Other Immunizations.** The Advisory Committee for Immunization Practices (ACIP) of the Centers for Disease Control and Prevention (CDC) and the American Academy of Pediatrics (AAP) recommend a series of routine immunizations for infants, children and adults (MMWR, 2006). These immunizations have dramatically decreased the rates of sickness and death from several infectious diseases, and several of the immunizations are a requirement for a student to enter school. The ACIP and the AAP recommend that the vast majority of these immunizations should be administered by the intra-muscular (IM) route, a procedure that puts those with FOP at risk for heterotopic ossification at the injection site (Lanchoney, *et al.*, 1995).

However, several vaccines can be given via the subcutaneous (SC) route and will still be effective in conferring protection against the specific disease. The vaccines that can be given by the SC route are:

- Measles, mumps, rubella (MMR)
- Meningococcal polysaccharide (MPSV)
- Pneumococcal polysaccharide (PPV)
- Polio vaccine, inactivated (IPV)

The vaccines listed below can be given only by the IM route. Administration by the SC or intradermal route may cause increased local irritation, induration, skin discoloration, inflammation and granuloma formation. The vaccines that the ACIP and the AAP have determined can be given by the IM route only are:

- Diphtheria, tetanus, pertussis (DTaP, DT, Tdap, Td)
- *Haemophilus influenzae* type b (Hib)
- Hepatitis A (HepA)
- Hepatitis B (HepB)
- Human papilloma virus (HPV)
- Pneumococcal conjugate (PCV)

For most individuals with FOP, the infant series of immunizations will have been completed before the diagnosis of FOP has been made. However, in those in whom FOP is diagnosed in infancy, there is a conflict regarding IM immunizations:

Should the individual with FOP not receive the IM immunizations to avoid the risk of heterotopic ossification at the injection site and thus be at risk of contracting serious disease that could have been prevented by the immunizations?

*Or*

Should the individual with FOP receive the IM immunizations and be protected against these diseases despite the substantial risk of heterotopic ossification and associated permanent disability?

The parents of the infant or child with FOP should discuss these serious questions with their pediatrician. However, any household contact of an FOP patient should definitely be vaccinated for all age-appropriate recommended immunizations.

In the near future, the Committee on Infectious Diseases of the American Academy of Pediatrics and the Advisory Committee on Immunization Practices of the CDC will meet to discuss this question. Therefore, it is hoped that we will soon have a definitive answer to the question. If and when an official recommendation is made regarding this question, it will be posted on the IFOPA website.

## **F. Limb Swelling & FOP**

Limb swelling is a common problem in patients who have FOP, yet little is known about this complication of the condition. In a published study, detailed medical records were reviewed on a large group of FOP patients who had a documented history of FOP to determine the prevalence and natural history of limb swelling (Moriatis et al., 1997). Acute swelling of the limbs occurred in association with flare-ups of the condition in nearly all cases. Acute swelling in the upper limbs was focal and nodular in contrast to acute swelling in the lower limbs, which was more diffuse. The intense angiogenesis and edema seen on histopathologic evaluation of preosseous FOP lesions may play a role in the pathogenesis of the limb swelling. In addition, proximal lesions in the limb may cause a mechanical blockage of distal limb lymphatic drainage thus causing or exacerbating the swelling.

The acute and often severe limb swelling seen with acute flare-ups of FOP is understandable on the basis of the intense inflammation, angiogenesis and capillary leakage demonstrable in the early FOP lesions. Limb swelling associated with an acute FOP flare-up may grow to extraordinary and alarming size and lead to extravascular compression of nerves and tissue lymphatics. The appearance of such massive acute swelling in the lower limbs can provoke serious considerations of a deep vein thrombosis. Massive tissue edema may last for 9-12 weeks after the onset of acute swelling. As fibrocartilaginous tissue matures into chondroosseous tissue and finally into bone, swelling diminishes. During the following six months, swelling may regress slowly or may persist as chronic limb swelling. As skeletal muscle in the lower limbs is replaced by heterotopic bone, the normal pumping action of the muscle is lost, further exacerbating lymphatic stasis and dependent edema. Progressive ankylosis of the joints continues inexorably and loss of mobility ensues, further increasing venous and lymphatic stasis and dependent edema (Moriatis et al., 1997).

Some patients who have advanced FOP involving the lower limbs have venous stasis and/or lymphedema. Definitive studies to exclude deep vein thrombosis may be difficult to obtain and interpret due to severe existing deformity and joint ankylosis from previous flare-ups. A decision to anticoagulate a patient should not be made without substantial evidence of deep vein thrombosis. The differential diagnosis of acute upper limb swelling is not nearly as difficult as is the differential diagnosis of acute lower limb swelling in patients who have FOP. Differences in the regional appearance of the FOP lesions cannot be explained at the present time, but may be due to mechanical factors affecting aponeuroses and fascial planes (Moriatis et al., 1997).

Limb swelling is often difficult to treat effectively in patients who have FOP. Non-steroidal anti-inflammatory medications and glucocorticoids generally have not been effective. Support stockings are poorly tolerated by most patients, and elevation of the affected limbs is often impossible because of ankylosis of the major joints, especially later in the disease process. Where tolerated, support stockings may be helpful. The use of pneumatic compression devices has not been evaluated. Additionally, many have reported anecdotal beneficial effects following treatments at lymphedema clinics.

## **G. Pressure Sores in FOP**

Skin breakdown and pressure sores are common and troublesome problems in individuals who have FOP. Skin breakdown can occur from increased pressure over normotopic or heterotopic bone. Pressure sores can develop suddenly, progress rapidly, and be difficult to treat (Kantanie, 2008). Preventive measures include:

- Frequent changes in position.
- Use of a pressure-reducing mattress or bed.
- Daily skin inspections.
- Adequate nutrition.

If a pressure sore is detected at an early stage when the skin is erythematous but there is no open sore, it will be much easier to treat. Pressure sores involving open wounds require considerably more care. Follow these suggestions as soon as a problem is identified (Thomas, 2001; Reddy et al., 2006; Mayo Clinic, 2008):

- Change positions frequently and use special cushions designed to relieve pressure.
- Keep the area clean to prevent infection. A stage I wound (no open skin) can be gently washed with water and mild soap. Anything more serious should be washed with saline (salt) solution, which can be obtained from a pharmacy. Avoid using antiseptics such as hydrogen peroxide or iodine which can damage the skin and delay healing.
- Use a special dressing/bandage that protects wounds and helps promote healing. Name brands include Tegaderm and Duoderm. These dressings help keep the wound moist (to promote cell growth) while keeping the surrounding tissue dry.
- If necessary, damaged tissue can be removed. A wound needs to be free of dead and/or infected tissue to heal properly. There are several ways that this can be done safely, even in FOP.
- Whirlpool baths can be helpful because they help keep the skin clean and naturally remove dead tissue.

## **H. Fractures in FOP**

In FOP, fractures can occur in both normotopic and heterotopic bone. Fractures of heterotopic bone occur commonly and heal rapidly. Elevation, rest, splinting, and local application of ice are often helpful in controlling pain and swelling, and may be supplemented by narcotic analgesia, as needed. Fractures of normotopic bone need to be carefully evaluated, as in any patient. Closed reduction and splinting is sufficient for most fractures. Open reduction or internal fixation is almost never warranted and can lead to rapid onset of heterotopic ossification. Healing may be delayed in osteoporotic bone. Nonunion has not been reported in FOP (Einhorn & Kaplan, 1994), but unpublished anecdotal reports suggest that glucocorticoids may delay healing of fractures in the normotopic skeleton of FOP patients.

## **I. Preventive Oral Healthcare in FOP**

Individuals with FOP have developmental anomalies of the temporomandibular joints (TMJs) (Connor & Evans, 1982; Renton et al., 1982; Carvalho et al., 2011). Spontaneous or post-traumatic ankylosis of the TMJs is common and leads to severe disability with resultant difficulties in eating and poor oral hygiene. Great care must be taken not to provoke flare-ups of the TMJ (Luchetti et al., 1996).

Preventive oral and dental health care measures are essential in patients with FOP, especially during childhood years (Young et al., 2007). Periodontic and preventative oral care is crucial to prevent long-term dental and oral complications in FOP patients. Ultrasonic tooth brushes with small heads and water piks may also help with dental hygiene. Fluoridation of water is suggested for all patients who have FOP. The use of high dose fluoride toothpaste is recommended along with use of fluoride gels and rinses to help prevent the need for restorative dental care. Chlorhexidine rinses are encouraged to prevent gingivitis and

tooth decay. Frequent flossing and brushing are necessary in patients with FOP as in anyone, but may be difficult due to limited jaw opening as FOP progresses. FOP patients who still have mouth opening can be treated with normal dental instruments as in unaffected individuals, but great care must be exercised to prevent overstretching of the TMJs during dental procedures. In patients who have ankylosed TMJs, professional instrumentation and special toothbrushes may be helpful, but are often limited to use on the buccal surfaces. Antimicrobial and fluoride rinses may be the only method to reach the lingual and palatal surfaces (Nussbaum et al., 2005). Patients with a high risk of dental caries or difficulty in maintaining good oral hygiene may request that their dentist professionally apply fluoride varnish or a bioerodible and fluoride resin. There is overwhelming evidence that these modalities are effective in inhibiting tooth demineralization (Donly, 2003; Lin et al., 2009).

## **J. Dental Anesthesia in FOP**

FOP patients have limited options for dental anesthesia. Mandibular blocks are forbidden as they will lead to ossification of the pterygoid muscles and rapid ankylosis of the TMJ (Luchetti et al., 1996). Infiltration anesthesia is difficult in the mandibular posterior molar areas of permanent teeth. Successful anesthesia in mandibular primary teeth can be achieved by infiltration through the dental pulp.

Interligamentary infiltration may be helpful, if performed carefully. However, in some patients, this type of local anesthesia may not be possible. General anesthesia may be needed for dental care in FOP patients (Nussbaum et al., 1996; Nussbaum et al., 2005).

## **K. General Anesthesia in FOP**

### *Preoperative preparation:*

Preparation for a surgical procedure in an FOP patient should follow the same guidelines and recommendations as for all un-affected individuals. The American Society for Anesthesiologists has posted recommendations and guidelines: **Patient Education Web Site for the American Society of Anesthesiologists (ASA)** on the following web site: <http://www.asahq.org/patienteducation.htm>. The reader will find answers to questions related to preoperative preparation, pain management, and awareness during surgery.

A preoperative visit and meeting with the anesthesiologist prior to the date of surgery is crucial for conducting a safe and smooth general anesthesia course. The anesthesiologist should become familiar with FOP, learn about the extent of the disease affecting the individual patient, and carefully plan the perioperative anesthesia care. In the case of a patient presenting with advanced disease, significant ankylosis of multiple joints, and/or limited mobility and co-morbidities, the anesthesiologist should plan to assemble a back-up team: an anesthesiologist and a surgeon experienced in emergency airway management. Sharing the anesthesia plan with the patient and the family is useful to diffuse apprehension and foster cooperation on the day of surgery.

The special care and the skills required by the anesthesiologist to treat an FOP patient may not be available at peripheral locations or community hospitals. In these situations, the referring physician, the patient, and the family should seek referral to a major medical center with practitioners who are skilled in the care of FOP patients.



### *Intraoperative management:*

Positioning. The operating room table should be adjusted according to patient's needs. Extra padding will help minimize soft tissue trauma during the surgical procedure.

Monitoring. Routine monitoring is required for most surgical procedures (ECG, non-invasive blood pressure, pulse oximeter, end-tidal CO<sub>2</sub>, and temperature). Significant co-morbidities, lengthy surgical procedures, or a compromised cardio-respiratory system may require the addition of additional monitors. In patients whose upper limbs are ankylosed in adduction and flexion, the application of a blood pressure cuff may be difficult or impossible. The cuff may be applied on the lower extremity. A thin layer of padding under the cuff may reduce the impact of the frequent inflations of the cuff on the extremity.

Intravenous access. Careful venipunctures are not a problem. An indwelling intravenous catheter may rarely lead to the formation of an ossified tract at the site of insertion. Therefore, the smallest intravenous catheter appropriate for the procedure is selected for insertion.

General anesthesia and sedation: The administration of general anesthesia and the maintenance of a patent airway are particularly challenging matters in patients who have FOP, and should be planned with exacting care. Guidelines for general anesthesia have been reported (Nussbaum et al., 2005).

Physicians and patients may be tempted to use sedation techniques and perform minor surgical procedures at an office-based or out-patient facility. The risks of catastrophic airway emergencies far outweigh the potential benefits of this option. Procedures should be performed only at facilities equipped with the skills and support systems necessary for a safe outcome. For patients with advanced disease, it is recommended that even minor procedures (colonoscopies, dental procedures) be performed at a major medical center under general anesthesia with a secured airway by endotracheal intubation.

Patients who can open the mouth: In patients who are able to open the mouth, it is imperative to avoid over-stretching the TMJ during direct laryngoscopy. Careful positioning of the patient and the head, maintenance of a sniffing position and the use of a Glidescope (GlideScope<sup>®</sup> Video laryngoscopes (GVL<sup>®</sup>) with minimal mouth opening is one approach of securing the airway. In cases where adequate mouth opening is questionable, an awake fiberoptic naso-tracheal intubation is recommended.

Patients who cannot open the mouth. In patients who present with fusion of the cervical vertebrae, limited mouth opening, or ankylosis of the TMJ, oral access for endotracheal intubation is not possible. For these patients, an awake fiberoptic naso-tracheal intubation under light sedation is recommended. This should be performed by well-trained anesthesia teams who are familiar and experienced with this type of procedure (Nussbaum et al., 2005; Tumolo et al., 2006). The team should consist of two experienced anesthesiologists. A back-up surgeon (usually an otorhinolaryngologist) experienced in performing tracheostomies should be present with an immediately available tracheotomy tray. Nasal fiberoptic endotracheal intubation is performed with attention to administration of vasoconstrictors to the nose and the use of lubricated nasopharyngeal tubes starting with a small one and increasing the diameter up to 32-34 Fr.

### *Postoperative pain management and regional anesthesia:*

Most patients with FOP present with advanced ossifications at the thoraco-lumbar area precluding access to spinal or epidural analgesia.

Postoperative pain management is accomplished with intravenous medications. Patients using patient controlled analgesia (PCA) devices should receive supplemental oxygen with careful monitoring of oxygenation at all times. Oral medications are prescribed to patients who can open the mouth.

All questions regarding general anesthesia should be directed to Dr. Zvi Grunwald (please see section X. for contact information).

## **L. Orthodontics & FOP**

Most people seek orthodontic care for aesthetic and functional reasons. For the FOP population, self image is as important as in the general population. Orthodontic therapy can be safely performed on patients with FOP who have normal or nearly normal oral opening (Luchetti et al., 1996).

Patients who have FOP often develop mandibular hypoplasia with a maxillary overbite and, therefore, orthodontic therapy may be considered. However, many patients find that the overbite provides a means of access for eating as well as for oral and dental hygiene. Posterior and anterior dental crossbites can have an effect on the TMJs and should be corrected. For children with functional TMJs and with anterior open bites that are less than 15 mms, orthodontics is not recommended as the overbite will facilitate nutrition and subsequent dental care if the TMJ does eventually ankylose.

When orthodontic care is considered, brief appointment times should be used to lessen stress on the TMJs. The use of nonextraction therapy is also recommended. To prevent the need for extractions in FOP patients, it may be advisable to align the anterior segments for aesthetics, leaving posterior dental crowding untreated. Crowded posterior teeth may be a better alternative than the risks of flare-up and TMJ ankylosis that can accompany an extraction (Levy et al., 1999).

## **M. Submandibular Flare-ups in FOP**

Submandibular flare-ups are among the most concerning of all flare-ups due to their potential for causing difficulties in breathing and swallowing. Rarely, however, does jaw movement become affected by flare-ups isolated to this region. Due to their significance for vital functions, submandibular flare-ups warrant special attention (Janoff et al., 1996; Leavitt et al., 2009).

A comprehensive study of submandibular swelling in patients with FOP was undertaken by Janoff et al. and published in 1996. Twelve (11%) of 107 patients who were studied had submandibular heterotopic ossification that was mistaken initially in seven of the patients for mumps, angioneurotic edema, abscess, mononucleosis, or neoplasm. Two male patients and ten female patients ranging in age from 6-47 years (mean: 21 years) were studied. Ten patients survived following assiduous precautionary measures. One patient who required emergency tracheostomy and ventilatory support also survived. Another patient died of inanition from chronic swallowing difficulty. An effective treatment program includes early identification of the submandibular flare-up, nutritional support, and glucocorticoid therapy. Submandibular swelling in patients who have FOP can be a medical emergency and requires intensive precautionary measures to avoid catastrophic clinical deterioration. These measures include avoidance of lesional manipulation, airway monitoring, and aspiration precautions. Submandibular swelling should be recognized as a variable feature of FOP with important potential additional clinical consequences (Janoff et al., 1996).

In a more recent case report of submandibular swelling in a patient with FOP (Leavitt et al., 2009) notes that submandibular flare-ups can be troublesome and endanger the airway or swallowing. The authors note that patients with FOP often have limited jaw movement and associated dental problems and that dental professionals often misdiagnose FOP patients with submandibular flare-ups as having dental abscesses or odontogenic infection. Making matters worse, any manipulation of the soft tissues of the mouth, or the head, or neck will hasten inflammation and worsen the clinical problems of heterotopic bone formation and thus also worsen the FOP flare-up in the submandibular region.

Patients with submandibular flare-ups of FOP must be properly diagnosed so that intensive precautionary measures to avoid catastrophic clinical deterioration can be instituted.

An important challenge in the care of patients with a submandibular flare-up of FOP is to effectively manage the acute symptoms and associated discomfort while avoiding meddlesome intervention that will likely exact the lesion.

On the basis of our extensive clinical experience, we recommend the following:

1. All physicians who treat patients with FOP should be aware that acute submandibular swelling may be a manifestation of the disease at any age and can occur during childhood in patients with rapid disease progression.
2. Diagnosis of FOP should be communicated to the attending physician so that the acute submandibular lesion can be managed in the context of the patient's underlying disease.
3. Manipulation of acute lesions must be avoided because even minor trauma can lead to catastrophic exacerbation with airway compromise.
4. Patients having an acute submandibular flare-up should sleep with their head elevated if possible to decrease the risk of airway obstruction.
5. Patients with submandibular flare-ups should be monitored closely during the acute swelling phase. They should be hospitalized immediately in the event of pending obstruction of the airway.
6. Food should be pureed or semi-solid. Clear liquids often provoke choking episodes during these flare-ups as the involved muscles are those that move the tongue at the floor of the mouth.
7. Patients should be encouraged to eat frequently to minimize weight loss.
8. Additional high calorie food supplements should also be considered.
9. Assiduous precautions should be undertaken to prevent food aspiration.
10. High dose oral glucocorticoids should be considered in the very early treatment of acute submandibular flare-ups. The glucocorticoid of choice is prednisone and the dose is 2 mgs/kg of bodyweight (up to 100 mgs) taken per oral once daily for four days at the earliest sign of an acute flare-up. While these flare-ups do not last longer than flare-ups at other locations, the functional consequences of flare-ups in the submandibular region may warrant a longer glucocorticoid treatment course or a second course of steroids if severe soft tissue swelling recurs after cessation of steroid use. If a second four-day course of high dose glucocorticoids is used, the steroids should be tapered slowly over the next two to three weeks. Following discontinuation of the

glucocorticoid therapy, non-steroidal anti-inflammatory medications or a cox-2 inhibitor can be considered for the next 6-8 weeks.

## **N. Hearing Impairment in FOP**

Hearing impairment is a common feature of FOP and occurs in approximately 50 percent of patients. The onset is usually in childhood and may be slowly progressive. Hearing loss is usually conductive in nature and may be due to middle ear ossification, but in some patients, the hearing impairment is neurologic in nature. Children with FOP should generally have audiology evaluations every other year; more often, if necessary. Hearing aids are often helpful and can diminish developmental problems due to hearing loss (Levy et al., 1999).

## **O. Kidney Stones & FOP**

Clinical observations prompted a worldwide survey of patient-members of the International Fibrodysplasia Ossificans Progressiva Association (IFOPA) on the disease burden of kidney stones. The survey examined risk factors for the development of kidney stones in FOP patients, and provided a basis for prevention of stones in this already devastating disease (Reviewed in Glaser et al., 2005).

Although geographical variation exists, patients with FOP have approximately a two-fold higher prevalence of kidney stones than the general population. Immobilization coupled with increased bone turnover is a significant risk factor in the development of kidney stones in this population. There has been no comprehensive study of stone composition in FOP patients.

A low fiber diet was the only dietary factor in this study to significantly increase the risk of developing kidney stones in this population, although deficient water intake and excess animal protein intake were associated with the condition. FOP patients with a history of urinary tract infections are at increased risk for developing kidney stones. Extracorporeal shock wave lithotripsy, uteroscopic stone removal, percutaneous nephrolithotomy, and laser lithotripsy have all been used as treatment modalities, but there are no long-term data to evaluate the safety or efficacy of one treatment over another.

Ideally, we would like to make recommendations to prevent kidney stones. This becomes increasingly important as FOP patients become progressively more immobilized. Patients should drink sufficient water to keep the urine volume above three liters daily. Patients should substitute whole wheat bread for white bread and eat natural fiber cereals. Patients should also limit their intake of Vitamin C and oxalate-rich foods, and refrain from adding salt to their food. Patients should not restrict dairy products; however, they should be careful not to overindulge either (reviewed in Glaser et al., 2005).

## **P. Rehabilitation Issues in FOP**

As heterotopic bone accumulates in FOP, range of motion is progressively lost, leading to near complete immobility. Present and future rehabilitation approaches should be focused on enhancing activities of daily living. Occupational therapy and vocational education consultations may be extremely useful. Passive range of motion must be avoided, as it will likely lead to disease exacerbations. Despite the widespread heterotopic ossification and progressive disability, most patients lead productive and fulfilling lives (Levy et al., 1999; Levy et al., 2005).

Many of the limitations exacerbated by disease progression can be ameliorated with thoughtful rehabilitation.

*Occupational Therapy Issues:* Dressing may be enabled with pull-over shirts and blouses, elastic waistbands, Velcro closures, sock donners (devices where the sock is placed over a cuff attached to a cord), elastic shoe laces, and long handled shoe horns and reachers. Raised toilet seats, custom-angled commodes, bedside urinals (shaped for men or women), and bidets all enable toileting. Widened doorways and grab bars increase bathroom safety and accessibility. Long-handled sponges, combs, or modified reachers, electric toothbrushes, water pics, and suction devices help insure cleanliness and personal hygiene.

Strategically placed stools and elevated platforms, long-handled eating utensils and straws, help at the dinner table. Meal preparation may be facilitated by electrical can and jar openers, cutting boards with spikes to hold food while it is prepared or cut, and rotating shelves (Lazy Susans). For individuals with limited ability to masticate, food may be ground-up or pureed.

Depending on the stage of disease progression, canes, walkers, crutches, and/or custom shoes may be necessary for mobility. For more severe limitations, power wheelchairs may be necessary. Considerations for power wheelchairs include customized seating, power seat elevation and depression, anterior and posterior tilt and recline function. Lap trays with mounts for laptop computers allow participation in work and school.

*Vocational and Educational Issues:* Because even minor trauma can trigger disabling heterotopic ossification, it is sensible to encourage intellectual pursuits and computer skills. Public school systems in the United States must provide each disabled child with an individualized educational plan, and an education in the least restrictive environment. Children are entitled to occupational, physical and speech therapy as well as classroom aides if indicated. Each state is required to offer some sort of vocational rehabilitation to help people with disabilities enter or remain in the work force.

*Transportation and Home Modification:* Vans can be customized to accept an FOP power chair. Ramps and lifts can be installed, roofs can be raised, floors can be lowered, new controls and motors can be installed to allow the van to “kneel”, lowering ground clearance to ease ascent into a van.

Home modifications include elimination or minimization of indoor steps, installation of grab bars, widened hallways, accessible bathrooms and kitchens. Environmental control units operate appliances, doors, televisions and telephones remotely. To facilitate sleep, there are tilt table beds that rotate from vertical to horizontal, specialized mattresses and overlays to redistribute pressure to provide comfort and protect skin integrity.

*Sexuality and reproduction:* Physical acts of sexual intimacy require tact and thoughtfulness. Pillows and bolsters may be necessary to support the unusual and inflexible postures. Genetic counseling and discussion of contraception are warranted for the sexually active or those who are considering such activity.

*Aquatic therapy* allows individuals to perform active range of motion, cardiopulmonary, and resistive exercise in a safe, low impact environment. Warm water can facilitate pain relief. Modified lifts, elevators or ramps may be necessary for pool entry and exit.

*Iontophoresis* involves the introduction of topically applied physiologically active ions (acetic acid, steroids) through the epidermis using continuous direct current. Anecdotal reports suggest that acetic acid iontophoresis may help restore some lost temporomandibular joint range of motion in FOP.

### **Q. Pregnancy Issues in FOP**

The decision to have a child is one of the most important and serious life decisions an individual or couple can make. Because FOP is an inherited disease, anyone (man or woman) with FOP will have similar concerns about passing the FOP mutation to his/her child. If a parent has FOP, the chance that the child will have FOP is fifty percent. Women, specifically, have additional matters to consider. In addition to the usual risks that any woman might encounter during pregnancy, a woman with FOP has additional concerns that must be carefully considered. Pregnancy in a patient with FOP is perilous, and poses substantial life-threatening risks to both the mother and child (Davidson et al., 1985; Thornton et al., 1987).

*Specific risks to the mother include, but are not limited to:*

1. Risk of FOP flare-ups during pregnancy. To protect the fetus, the use of palliative medications that are often used to treat flare-ups may have to be limited.
2. Risk of breathing difficulties during the latter part of pregnancy. FOP causes severe limitation of expansion of the chest wall due to developmental anomalies in the costovertebral joints. Breathing problems can also arise due to bone formation in the chest muscles. As the fetus grows in the womb, it presses upward on the diaphragm. This upward pressure on the diaphragm further limits the space for the mother's lungs to expand resulting in increased difficulty breathing. Breathing may be rendered even more difficult if the mother has already formed heterotopic bone in the abdominal wall that restricts outward growth of the fetus. As a result, the growing baby will further press upwards on the mother's diaphragm, restricting breathing even further.
3. Risk of childbirth complications. Caesarian section is necessary for a mother with FOP due to the pelvic deformity, joint fusions, and decreased plasticity of the birth canal that will not safely accommodate a normal vaginal delivery. It would not be safe or even possible to have normal childbirth due to the physical limitations and mobility restrictions of FOP.
4. Risk of the general anesthesia for Caesarian delivery. Caesarian delivery is a surgical procedure requiring anesthesia. Due to FOP, regional anesthetics are technically unfeasible, dangerous, and can not be used. General anesthesia is required. In addition to the dramatic increased risks to the mother, general anesthetics pose substantial risks to the fetus/newborn baby (see below).
5. Risk of phlebitis and pulmonary embolism. These potentially life-threatening complications can arise due to the severe immobility of FOP. The added constraints of pregnancy, such as extended bedrest mandated by a high-risk pregnancy along with the lower limb edema that invariably occurs in the last trimester of pregnancy further increase the risk of these life-threatening complications.

*Specific risks to the child include, but are not limited to:*

1. Risk that the child may have FOP. If a parent has FOP, the chance that the child will have FOP is fifty percent.

2. Risk of prematurity. The mother may not be able to carry to full-term due to breathing difficulties. As a result, there is a severe risk of premature delivery. Numerous lifelong consequences are often associated with premature birth.
3. Risk of severe fetal distress. The risk of severe fetal distress, a condition in which the fetus is at risk of dying or suffering severe brain injury, is primarily due to hypoxia (diminished oxygen to the fetus). This complication may result from maternal breathing difficulties or other unrecognized problems later in pregnancy (see above).
4. Risk of cerebral palsy. There is a high risk of cerebral palsy due to oxygen deprivation to the fetus, especially if fetal distress occurs during the latter part of pregnancy or during delivery.
5. Risk of complications from general anesthesia. There is a high risk of complications to the newborn resulting from general anesthesia during Caesarian section (see above). General anesthesia is required, as the more preferable local or regional anesthesia is technically impossible when the mother has FOP. At delivery, there should be a team skilled in resuscitation of high risk infants.

Additional complications to consider are: Who will care for the mother during the complications and added stress of pregnancy? Who will care for the child if the mother is disabled from FOP? What is the role of the father, siblings, and grandparents in the care of the newborn child?

Although it is possible for a woman with FOP to carry a child to term, and at least four known instances have been reported in the medical literature, there are substantial life-threatening risks to both the mother and child. Pregnancy in FOP should never be undertaken without serious consideration and family planning. Unwanted pregnancies should be assiduously avoided. Independent genetic counseling is available, if desired.

Should a pregnancy occur, guidance and care at a high-risk pregnancy center are imperative. At least two lives are at stake: that of the mother and that of the child. In addition, the lives of many others will be impacted by a pregnancy in a mother with FOP – specifically, those of other family members who, by necessity, are involved in the consequences of any such occurrence.

In summary, pregnancy in FOP poses major life-threatening risks to both mother and child as well as life-altering consequences to the entire family that must be carefully considered and balanced.

## IV. CURRENT TREATMENT CONSIDERATIONS

At the present time, there are no established preventions or treatments for FOP. The disorder's rarity, variable severity, and fluctuating clinical course pose substantial uncertainties when evaluating experimental therapies. To date, there have been no double-blinded randomized placebo-controlled clinical trials to assess the relative efficacy of any potential therapy.

### REPORT FROM THE INTERNATIONAL FOP CLINICAL CONSORTIUM: A GUIDE FOR CLINICIANS

An international panel of physicians has reviewed and updated current treatment considerations in FOP (Table 1). The panel reviewed many current and potential treatment options for this disorder. The unpredictable nature of FOP has made controlled trials extremely difficult to perform, but all agreed that the obstacles were surmountable.

In evaluating each potential treatment, the group focused on the known mechanism of action of the treatment as it relates to the proposed pathogenesis of FOP. Consideration for use of each medication was made based on balancing the clinical uncertainty of each agent when used to treat FOP against the compassionate need to adequately and safely control the disabling symptoms of the disease, especially during flare-ups. Each pharmacologic agent was classified into one of three categories based on experimental or anecdotal experience with the drug as well as knowledge of each drug's safety profile.

**Class I:** Medications that have been widely used to control symptoms of the acute flare-up in FOP (swelling and pain), with anecdotal reports of favorable clinical results and generally minimal side effects. *Examples:* Short-term use of high-dose corticosteroids, and use of non-steroidal anti-inflammatory drugs (NSAIDs) including the new anti-inflammatory and anti-angiogenic cox-2 inhibitors.

**Class II:** Medications that have theoretical application to FOP, are approved for the treatment of other disorders, and have limited and well-described effects. *Examples:* Leukotriene inhibitors, mast cell stabilizers, and aminobisphosphonates (Pamidronate; Zoledronate).

**Class III:** Investigational new drugs  
*Examples:* Signal transduction inhibitors, monoclonal antibodies targeting ACVR1, and retinoic acid receptor gamma agonists (presently under development).

**PHYSICIANS TREATING PATIENTS WHO HAVE FOP SHOULD KEEP IN MIND THAT NONE OF THESE MEDICATIONS (OR ANY OTHER MEDICATIONS TO DATE) HAVE BEEN PROVEN TO ALTER THE NATURAL HISTORY OF FOP.**

We emphasize that this report reflects the authors' experience and opinions on the various classes of symptom-modifying medications, and is meant only as a guide to this controversial area of therapeutics. Although there are common physical features shared by every person who has FOP, there are differences among individuals that may alter the potential benefits or risks of any medication or class of medications discussed here. The decision to use or withhold a particular medication must ultimately rest with an individual patient and his or her physician.



**Class I Medications:** For acute flare-ups, the immediate use of prednisone at a dose of 2 mg/kg/day (up to 100 mg) can be considered as a single daily dose for a maximum of four days. For maximal beneficial effect, the prednisone should be started within 24 hours of the onset of a flare-up, which corresponds to the earliest phase of acute and intense lymphocytic infiltration into skeletal muscle. If the flare-up is more than two days old, prednisone is generally less effective. If the flare-up responds to the medication but recurs when the prednisone is discontinued, a repeat 4-day course with a subsequent 10-day taper can be considered. Prednisone should generally not be used for flare-ups on the chest or trunk, as it is difficult to judge the exact onset of a new flare-up. Prolonged or chronic use of corticosteroids is of no benefit, may accelerate heterotopic ossification, is harmful systemically, and should not be considered. Furthermore, suppression of the pituitary-adrenal axis is likely to occur with chronic or long-term use and can have long-term harmful effects. The use of prednisone is meant only to suppress or abort the early inflammatory events of an acute FOP flare-up, and potentially suppress the subsequent death of skeletal muscle in the earliest stages of an FOP flare-up.

When the prednisone is discontinued (or if a flare-up existing for more than 48 hours is being considered for treatment), treatment may be considered with a non-steroidal anti-inflammatory agent. A cyclooxygenase-2 (cox-2) inhibitor can be used instead of a traditional NSAID (Table 1). Compassionate off-label use of cox-2 inhibitors has been reported anecdotally in children with FOP, as young as two years of age. As with all non-steroidal anti-inflammatory medications, gastrointestinal precautions should prevail. If long-term use of the cox-2 inhibitors is considered, serum liver and kidney function tests should be monitored. Cox-2 inhibitors should be used with caution in FOP patients with a history of cardiovascular disease or in older FOP patients who are severely immobilized or completely non-ambulatory.

**Class II Medications** can be added at the physicians' discretion. The leukotriene inhibitor montelukast (Singulair) can be considered at a dose of 5 mg or 10 mg per oral daily (depending upon age; see Table 1) in order to help abrogate the inflammatory symptoms of an FOP flare-up. The combined use of montelukast and a non-steroidal anti-inflammatory agent or a cox-2 inhibitor can be considered as a long-term treatment, following the discontinuation of a single 4-day steroid burst.

Sodium cromolyn is a generally well-tolerated mast cell inhibitor. However, oral absorption is poor, and its potential effectiveness in FOP is unknown.

The clinical rationale and early anecdotal experience with cyclical intravenous administration of the aminobisphosphonates is described in detail in the body of this report.

**Class III Medications** are under development and are not yet available.

## V. CLASSES OF MEDICATIONS (TABLE 1)

### CLASS I MEDICATIONS

GENERIC	TRADE	CLASS	PROPOSED MECHANISM OF ACTION AS IT RELATES TO FOP	DOSING	MAJOR SIDE EFFECTS
<b>Prednisone</b>	<b>Prednisone</b>	Corticosteroid	<p>Decreases lymphocyte and macrophage recruitment and tissue infiltration; potent anti-inflammatory drug: Decreases inflammation, swelling and edema especially when involving jaw, throat, and major joints.</p> <p><i>Do not use for flare-ups involving chest or back (see text).</i></p>	<p>2 mg/kg once daily in AM by oral administration (PO) x 4 days maximum. Max dose: 100 mg/day. If flareup recurs immediately, may repeat 4 day course with longer taper. May also use longer treatment with taper for flare-ups in the submandibular region, especially those that affect breathing or swallowing. Should be started within 24 hours of the onset of a flare-up for maximal effectiveness. With the exception of life-threatening sub-mandibular flare-ups, do not use if the flare-up is more than two days old. (Medication should be taken with food).</p> <p>FOR PATIENTS IN INDIGENOUS REGIONS, ANTI-PARASITIC PRECAUTIONS MAY BE NECESSARY</p> <p>-----</p> <p>Alternatively, high dose intravenous corticosteroid (Prednisolone) therapy may be considered, but must be performed during an inpatient hospitalization to monitor for potentially dangerous side-effects of hypertension. The standard protocol for IV corticosteroid therapy is as follows:  Day 1: 20-30 mg/kg of prednisolone IV  Day 2: No medication  Day 3: 20-30 mg/kg of Prednisolone IV  Day 4: No medication  Day 5: 20-30 mg/kg of Prednisolone IV.  <b>Total daily dose not to exceed 1000 mg.</b></p>	<ul style="list-style-type: none"> <li>~ avascular necrosis of hip</li> <li>~ diabetes-cataracts</li> <li>~ osteoporosis</li> <li>~ chronic dependency</li> <li>~ immune suppression</li> <li>~ adrenal suppression</li> <li>~ growth retardation</li> <li>~ acne</li> <li>~ peptic ulcers</li> <li>~ hypertension</li> <li>~ glaucoma</li> <li>~ weight gain</li> <li>~ skin bruising</li> <li>~ sleep and mood disturbance</li> </ul>
<b>Ibuprofen</b>	<b>Advil Motrin</b>	Non-steroidal anti-inflammatory medication (non-specific cox-1 and cox-2 inhibitor)	Anti-inflammatory and anti-angiogenic; symptomatic relief during a flare-up; Potential use in prevention by inhibiting production of inflammatory prostaglandins	<p>Peds: 4-10 mg/kg PO every 6 hrs, as needed. Adult: 200-800 mg PO every 6 hrs, as needed. (Medication should be taken with food).</p>	<ul style="list-style-type: none"> <li>~ gastrointestinal bleeding</li> <li>~ impaired renal function</li> </ul>

<b>Indomethacin</b>	<b>Indocin</b>	Non-steroidal anti-inflammatory medication (non-specific cox-1 and cox-2 inhibitor)	Anti-inflammatory and anti-angiogenic; symptomatic relief during a flare-up; Potential use in prevention by inhibiting production of inflammatory prostaglandins	Peds: 2-4 mg/kg/day PO; or 150-200 mg/day (whichever is less); divided tid Adult: 50 mg PO tid or Indocin – SR (sustained release) at a dose of 75 mg. PO bid. (Medication must be taken with food).	~ gastrointestinal bleeding ~ impaired renal function
<b>Piroxicam</b>	<b>Feldene</b>	Non-steroidal anti-inflammatory medication (non-specific cox-1 and cox-2 inhibitor)	Anti-inflammatory and anti-angiogenic; symptomatic relief during a flare-up; Potential use in prevention by inhibiting production of inflammatory prostaglandins	Adult: 20 mg PO once daily (medication should be taken with food).	~ gastrointestinal bleeding ~ impaired renal function
<b>Celecoxib</b>	<b>Celebrex</b>	Cyclo-oxygenase-2 inhibitor (highly selective)	Anti-inflammatory and potent anti-angiogenic; symptomatic relief during a flare-up; Potential use in prevention by inhibiting production of inflammatory prostaglandins	Peds and Adults: 100-200 mg po bid for maintenance, at discretion of M.D. -For acute & chronic flare-ups, not to exceed maximum anti-angiogenic dose of 250 mgs/M <sup>2</sup> po bid <u>or</u> 6 mg/kg po bid (whichever is lower; rounded-up or rounded-down to the closest multiple of 100 mg) and not to exceed a maximum total daily dose of 600 mgs. for more than 16 months. Medication should be taken with a fatty snack for maximum absorption. Although used compassionately in children, not yet approved for pediatric use. -Patients should be monitored for adequate hepatic and renal function. -Use with caution in FOP patients with a history cardiovascular disease or in older FOP patients who are severely immobilized or completely non-ambulatory. - MUST NOT BE TAKEN BY PATIENTS WHO ARE ALLERGIC TO SULFONAMIDES OR BY PATIENTS WITH ASPIRIN-SENSITIVE ASTHMA.	~ gastrointestinal bleeding ~ impaired renal function ~concern about cardiovascular and cerebrovascular risks  ~NOT TO BE TAKEN BY PATIENTS WITH KNOWN ALLERGIES TO SULFONAMIDES OR BY PATIENTS WITH ASPIRIN-SENSITIVE ASTHMA
<b>Nabumetone</b>	<b>Relafen</b>	Non-steroidal anti-inflammatory Medication (mainly Cox-2 inhibitor but also non-specific activity)	Anti-inflammatory and anti-angiogenic; symptomatic relief during a flare-up; Potential use in prevention by inhibiting production of inflammatory prostaglandins	Adults: 1000 mg PO once or twice daily. May be useful for individuals who have allergy to sulfonamides and thus cannot use Celebrex	~gastrointestinal bleeding ~impaired renal function

## CLASS II MEDICATIONS

GENERIC	TRADE	CLASS	PROPOSED MECHANISM AS IT RELATES TO FOP	DOSING	MAJOR SIDE EFFECTS
Montelukast	Singulair	Leukotriene receptor antagonist	Blocks inflammatory mediators; complementary action to cyclooxygenase inhibitors.	Peds (2-5 yo): 4 mg PO at bedtime 6-14 yo: 5 mg PO at bedtime Adults: 10 mg PO at bedtime	Generally well-tolerated. Rarely: angioedema, headache, flu-like syndrome, fatigue, abdominal pain; possible association with behavior/mood changes, suicidal thinking and behavior, and suicide. Patients should be monitored for changes in behavior and mood.
Cromolyn	Gastrocrom	Mast cell stabilizer	Reduces mast cell degranulation, but poorly absorbed from GI tract. May be more effective if used chronically	Peds (0-2 yo): 20 mg/kg/d PO div qid; (2-12 yo): 100 mg PO qid Adult: 200 mg PO qid	Generally extremely well-tolerated. Rarely: throat irritation, dry throat, cough, bitter taste.
Pamidronate	Aredia	Amino-bisphosphonate	Anti-angiogenic; possibly anti-inflammatory; potential inhibition of early angiogenic fibroproliferative lesion; well-established effects on decreasing bone remodeling in normotopic skeleton and in protecting normotopic skeleton from profound osteopenic effects of chronic intermittent high dose glucocorticoids.	Peds (2-3 yo): 0.75 mg/kg/day by slow IV infusion for three days; For children older than 3 yo and for adolescents and adults: 1.0 mg/kg/day for three days. Medication should be infused slowly each day over 4-5 hours. <b>Note:</b> On the first day of the first cycle of treatment, the patient must receive half the dose. In case of fever, give standard acetaminophen treatment. The 3-day cycle of treatment should be repeated no more than 4 times annually. For dilution instructions, see text. Patients should have the following blood tests checked prior to Pamidronate treatment: serum calcium, phosphate albumin, alkaline phosphatase, 25-hydroxyvitamin D, BUN, creatinine, CBC. All patients should receive adequate	Generally well-tolerated. There are no known interactions with other medications. An acute phase reaction characterized by fever, malaise, and myalgia occurs commonly during IV infusion of Pamidronate and may persist for 18-24 hours. Pre-treatment with acetaminophen may lessen symptoms. In case of fever or other symptoms of acute phase reaction, give standard acetaminophen treatment. Pamidronate should not be used in patients who are hypocalcemic as tetany may result. Daily oral calcium and vitamin D supplementation should be provided to all
Zoledronate	Zometa	Amino-bisphosphonates	Anti-angiogenic; possibly anti-inflammatory; potential inhibition of early angiogenic fibroproliferative lesion; well-established effects on decreasing bone remodeling in normotopic skeleton and in protecting normotopic skeleton from profound osteopenic effects of chronic intermittent high dose glucocorticoids.	supplemental dietary calcium and vitamin D daily during and indefinitely following Pamidronate treatment. Photographs and clinical measurements of the flare-up should be obtained prior to treatment and daily thereafter for 14 days. Plain radiographs of the affected area should be obtained prior to treatment and 6 weeks thereafter to document the formation of any heterotopic ossification.  Adult (18.y.o and older): 5 mg by slow IV infusion over 30 minutes. Not for use in children. Patients should have the following blood tests checked prior to Zoledronate treatment: serum calcium, phosphate albumin, alkaline phosphatase, BUN, creatinine, CBC. All patients should receive adequate supplemental dietary calcium and vitamin D daily during and indefinitely following Pamidronate treatment. Photographs and clinical measurements of the flare-up should be obtained prior to treatment and daily thereafter for 14 days. Plain radiographs of the affected area should be obtained prior to treatment and 6 weeks thereafter to document the formation of any heterotopic ossification.	patients who receive Pamidronate (not just on days of infusion, but daily on a continual basis for at least two weeks). Frequent high-dose use of aminobisphosphonates in children can lead to osteopetrosis and possibly low energy femoral fractures. See also cautions in text for osteonecrosis of jaw.  Generally well-tolerated. There are no known interactions with other medications. An acute phase reaction characterized by fever, malaise, and myalgia occurs commonly during IV infusion of Zoledronate and may persist for 18-24 hours. Pre-treatment with acetaminophen may lessen symptoms. In case of fever or other symptoms of acute phase reaction, give standard acetaminophen treatment. Zoledronate should not be used in patients who are hypocalcemic as tetany may result. Daily oral calcium and vitamin D supplementation should be provided to all patients who receive Zoledronate (not just on days of infusion, but daily on a continual basis for at least two weeks). Frequent high-dose use of aminobisphosphonates in children can lead to osteopetrosis and possibly low-energy femoral fractures. See also cautions in text for osteonecrosis of jaw.

### CLASS III MEDICATIONS

GENERIC	TRADE	CLASS	PROPOSED MECHANISM OF ACTION AS IT RELATES TO FOP	DOSING	MAJOR SIDE EFFECTS
ACVR1/ALK2 Signal Transduction Inhibitor	Dorsomorphin Derivatives	Signal Transduction Inhibitor	Blocks ACVR1/ALK2 signal transduction	Not applicable at present time; under development	Not yet determined
Monoclonal Antibody Against ACVR1/ALK2	mAb-FOP	FOP Receptor Antibody	Blocks Receptor at Cell Surface	Not applicable at present time; under development	Not yet determined
Retinoic Acid Receptor- $\gamma$ Agonists	-----	RAR- $\gamma$ Agonists	Inhibits Chondrogenesis	Not applicable at present time; under development	Not yet determined

## VI. SUMMARY OF KEY PRACTICE POINTS

This very brief guide will summarize the current symptomatic management of FOP (Kaplan et al., 2008).

**Activities:** Avoid soft tissue injuries, contact sports, overstretching of soft tissues, and muscle fatigue. Avoid biopsies, surgical removal of heterotopic bone, intramuscular injections, and all non-emergent surgical procedures.

**Anesthesia:** If general anesthesia is required, perform awake intubation by nasotracheal fiber-optic technique. Highly-skilled FOP-aware anesthesiologists should be present for all elective intubations.

**Falls:** Locked upper limbs may accentuate head and neck trauma from falls. Epidural hematomas are common (surgical emergency). Use protective headgear in children who have upper limb involvement. All head and neck injuries must be evaluated immediately on an emergent basis.

**Flare-up: (Back/chest):** Use non-steroidal anti-inflammatory medications or cox-2 inhibitors with GI precautions. Use analgesics, muscle relaxants, and local applications of ice packs, as needed.

**Flare-up: (Limbs/throat):** Prednisone – 2 mgs/kg once daily (up to 100 mgs daily) in AM (per oral) for four days; begin within first 24 hours of flare-up. Keep medication on-hand for emergencies. Use analgesias and/or muscle relaxants, as needed, with GI precautions. Local application of ice packs may also be helpful.

**Flare-ups (Protection):** Most flare-ups result from over-use and soft tissue injuries. Prednisone - 2 mgs/kg, (per oral) once daily for three days to prevent flare-up after severe soft-tissue injury. Do not use after minor bumps or bruises.

**Hearing:** Conductive hearing impairment is common. Perform periodic audiology evaluations. Hearing aids may improve conductive hearing loss.

**Immunizations:** Avoid all intramuscular immunizations. Subcutaneous immunizations are acceptable when FOP is quiescent. Avoid immunizations during flare-ups.

**Influenza:** Administer influenza vaccines subcutaneously, but never during flare-ups. Avoid live attenuated flu vaccine as it may cause flu-like symptoms and exacerbate FOP. Household contacts of FOP patients should be immunized annually. Cough suppression may alleviate undue stress on chest musculature.

**IV's:** Superficial IV access and venipuncture is acceptable. Traumatic IV's and arterial punctures may cause heterotopic ossification.

**Limb swelling:** Lymphedema and transient neuropathy may occur with flare-ups of limbs. Elevate legs while sleeping and recumbent. Use support stockings. Take one baby aspirin daily with food. Rule-out deep vein phlebitis with Doppler ultrasound.

**Occupational therapy (OT):** Perform periodic OT evaluations as activities of daily living change.

**Physiotherapy:** Avoid passive range of motion. Warm water hydrotherapy may be helpful.

**Prednisone:** For flare-ups (as noted above), pre-operatively and for three days post-operatively (for emergent procedures and for minor and elective procedures including dental surgery), and for prophylaxis following major soft tissue injury (severe trauma).

**Pulmonary function:** Perform baseline pulmonary function tests (PFTs) and echocardiogram. Repeat periodically. Supplemental oxygen should not be used in an unmonitored setting.

**School:** Use school aides to protect and assist children. Request medical letter and preschool evaluation.

**Surgery:** Avoid surgery, except in emergencies.

**Teeth:** Avoid mandibular blocks, over-stretching of the jaw, and muscle fatigue.

## VII. CONCLUSIONS

In the book “Dark Remedy: The Impact of Thalidomide and Its Revival as a Vital Medicine,” there is a poignant discussion about the utility of double-blind randomized placebo-controlled studies as the “gold standard” for medication assessment. The authors write that our job as disciplined scientists is “to find the right questions to ask, the right tests to perform, and then to eliminate from interpretation of the data any expectations, assumptions, biases, or hopes that we may have in order to see the significance of the results with objective clarity. That clarity can make the difference between finding a cure for an incurable disease and raising false hopes for millions.” (Stephens & Brynner, 2001). There is little doubt that the testing of drugs for FOP, either for prevention or treatment, will require the same stringent principles and strategy.

A physician treating a patient with FOP must never withhold an available medication or treatment that may be truly helpful, but those medications must also be tested with scientific clarity to determine if they are, in fact, truly helpful or just simply the products of wishful thinking. As the Roman dramatist Terence warned more than two thousand years ago, “One easily believes what one earnestly hopes for.” In the absence of clear evidence-based research from controlled clinical trials, it is difficult to advocate a particular therapy with enthusiasm. Although it is appealing to attempt to swim across multiple therapeutic currents to safety, the waters of FOP are deep and dangerous. The carefully designed and well-controlled clinical trial may ultimately be the safest bridge across these troubled waters of FOP. Such an approach will require the patience and fortitude of the entire FOP community. In the meanwhile, the physician caring for a patient with FOP must constantly review evolving scientific information and chart the safest, and most responsible course for the patient until the enduring bridges are built and their safety and efficacy verified.

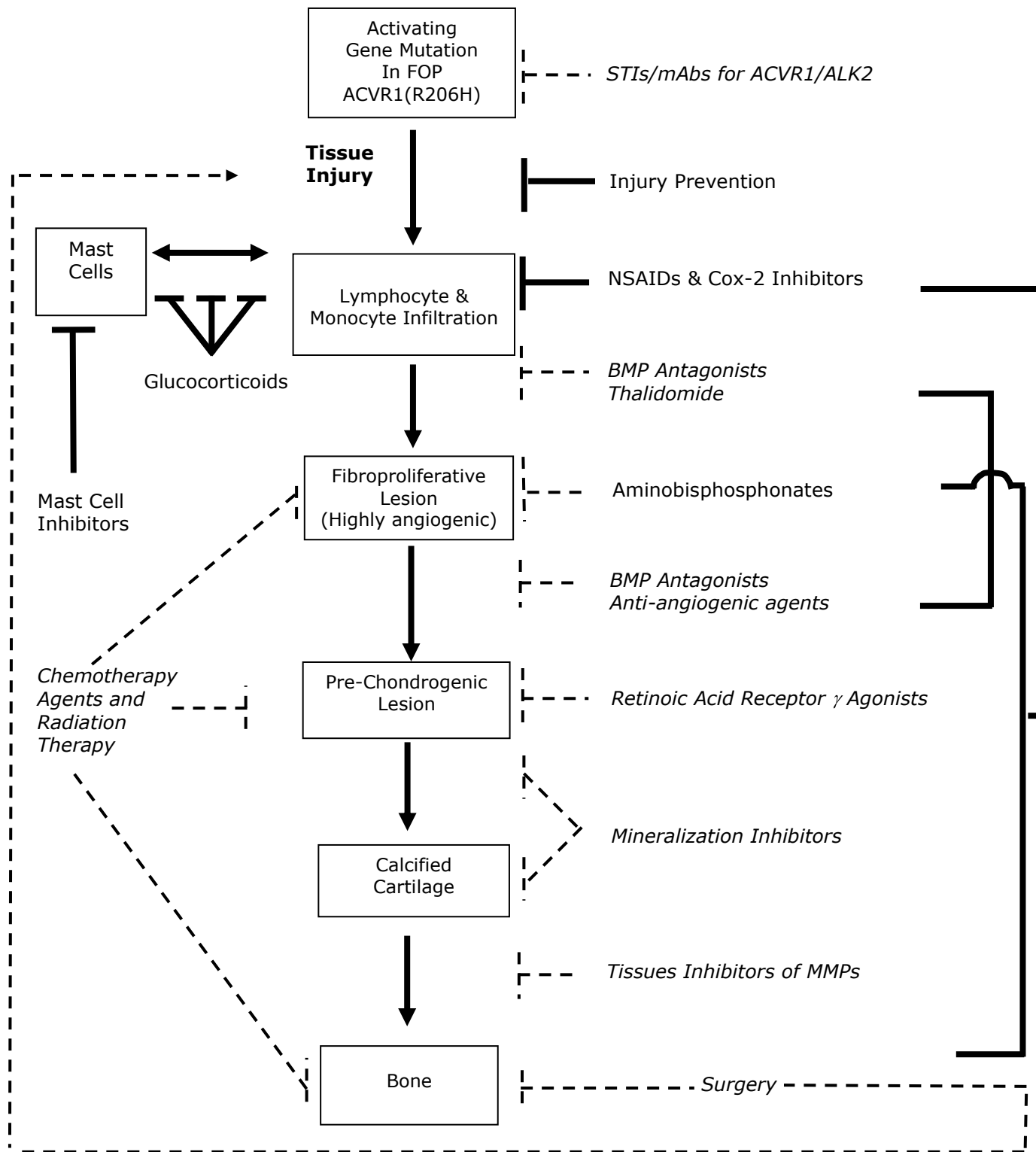


## **VIII. ACKNOWLEDGMENTS**

The authors would like to thank Kamlesh Rai for her diligent help and extensive support over many months in the preparation and revision of this document.

This work was supported in part by The International FOP Association, The Center for Research in FOP and Related Disorders, The Ian Cali Endowment, The Weldon Family Endowment, The Isaac & Rose Nassau Professorship of Orthopaedic Molecular Medicine, The Rita Allen Foundation, The Betty Laue Resource Center, and the Friends and Families of FOP patients worldwide.

**FIGURE 1: SYMPTOMATIC TREATMENT SCHEMA IN FIBRODYSPLASIA OSSIFICANS PROGRESSIVA**



- ( □ ) Boxes indicate known features of FOP
- ( → ) Arrows indicate causative factors, interactions, or stage-progression
- ( ┘ ) Blunt-end lines indicate hypothetical interventions
- ( - - ) Italics and Broken lines indicate treatments not currently recommended

**See Text for Details**

## IX. REFERENCES

### I. THE CLINICAL AND BASIC SCIENCE BACKGROUND OF FOP

#### A. Introduction

Connor JM, Evans, DA. Fibrodysplasia ossificans progressiva (FOP): the clinical features and natural history of 34 patients. **J Bone Joint Surg Br** 64: 76-83, 1982

Kaplan FS, Glaser DL. Thoracic insufficiency syndrome in patients with fibrodysplasia ossificans progressiva. **Clin Rev Bone Miner Metab** 3: 213-216, 2005

Kaplan FS, Glaser DL, Pignolo RJ, Shore EM. Introduction. Fibrodysplasia ossificans progressiva. **Clin Rev Bone Miner Metab** 3: 175-177, 2005

Kaplan FS, Glaser DL, Shore EM. Fibrodysplasia (myositis) ossificans progressiva. In Favus MJ (ed). **Primer on the Metabolic Bone Diseases and Disorders of Mineral Metabolism - Sixth Edition**. The American Society for Bone and Mineral Research, Washington, DC., pp. 450-453, 2006.

Kaplan FS, LeMerrer M, Glaser DL, Pignolo RJ, Goldsby RE, Kitterman JA, Groppe J, Shore EM. Fibrodysplasia ossificans progressiva. **Best Pract Res Clin Rheumatol** 22; 191-205, 2008

Kaplan FS, Xu M, Seemann P, Connor JM, Glaser DL, Carroll L, Delai, P, Xu M, Seemann P, Connor JM, Glaser DL, Carroll L, Delai P, Fastnacht-Urban E, Forman SJ, Gillessen-Kaesbach G, Hoover-Fong J, Köster B, Pauli RM, Reardon W, Zaidi S-A, Zasloff M, Morhart R, Mundlos S, Groppe J, and Shore EM. Classic and atypical fibrodysplasia ossificans progressiva (FOP) phenotypes are caused by mutations in the bone morphogenetic protein (BMP) type I receptor ACVR1. **Hum Mutat** 30, (3):379-390, 2009

Kaplan FS, Shore EM, Connor JM. Fibrodysplasia ossificans progressiva (FOP). In Royce PM, Steinmann B (eds). **Connective Tissue and Its Heritable Disorders**. New York, Wiley-Liss, Inc., pp. 827-840, 2002

McKusick VA. **Heritable Disorders of Connective Tissue**. Ed. 4. St. Louis, C.V. Mosby, 1972

Smith R. Fibrodysplasia (myositis) ossificans progressiva. **Clin Orthop** 346: 7-14, 1998

#### B. Classic Clinical Features of FOP

Cohen RB, Hahn GV, Tabas J, Peeper J, Levitz CL, Sando A, Sando N, Zasloff M, Kaplan FS. The natural history of heterotopic ossification in patients who have fibrodysplasia ossificans progressiva. **J Bone Joint Surg Am** 75: 215-219, 1993

Kaplan FS, Glaser DL, Shore EM, Deirmengian GK, Gupta R, Delai P, Morhart P, Smith R, Le Merrer M, Rogers JG, Connor JM, Kitterman JA. The phenotype of fibrodysplasia ossificans progressiva. **Clin Rev Bone Miner Metab** 3: 183-188, 2005

Kaplan FS, Zasloff MA, Kitterman JA, Shore EM, Hong CC, Rocke DM. Early mortality and cardiorespiratory failure in patients with fibrodysplasia ossificans progressiva. **J Bone Joint Surg Am** 92: 686-691, 2010.

Rocke DM, Zasloff M, Peeper J, Cohen RB, Kaplan FS. Age and joint-specific risk of initial heterotopic ossification in patients who have fibrodysplasia ossificans progressiva. **Clin Orthop** 301: 243-248, 1994

### **C. Other Skeletal Anomalies In FOP**

Deirmengian GK, Hebela NM, O'Connell M, Glaser DL, Shore EM, Kaplan FS. Proximal tibial osteochondromas in patients with fibrodysplasia ossificans progressiva. **J Bone Joint Surg Am** 90: 366-374, 2008

Kaplan FS, LeMerrer M, Glaser DL, Pignolo RJ, Goldsby RE, Kitterman JA, Groppe J, Shore EM. Fibrodysplasia ossificans progressiva. **Best Pract Res Clin Rheumatol** 22, 191-205, 2008

Kaplan FS, Xu M, Seemann P, Connor JM, Glaser DL, Carroll L, Delai P, Xu M, Seemann P, Connor JM, Glaser DL, Carroll L, Delai P, Fastnacht-Urban E, Forman SJ, Gillessen-Kaesbach G, Hoover-Fong J, Köster B, Pauli RM, Reardon W, Zaidi S-A, Zasloff M, Morhart R, Mundlos S, Groppe J, and Shore EM. Classic and atypical fibrodysplasia ossificans progressiva (FOP) phenotypes are caused by mutations in the bone morphogenetic protein (BMP) type I receptor ACVR1. **Hum Mutat** 30, (3):379-390, 2009

Schaffer AA, Kaplan FS, Tracy MR, O'Brien ML, Dormans JP, Shore EM, Harland RM, Kusumi K. Developmental anomalies of the cervical spine in patients with fibrodysplasia ossificans progressiva are distinctly different from those in patients with Klippel-Feil syndrome. **Spine** 30: 1379-1385, 2005

### **D. Radiographic Features of FOP**

Kaplan FS, Strear CM, Zasloff MA. Radiographic and scintigraphic features of modeling and remodeling in the heterotopic skeleton of patients who have fibrodysplasia ossificans progressiva. **Clin Orthop** 304: 238-247, 1994

Kaplan FS, Glaser DL, Shore EM, Deirmengian GK, Gupta R, Delai P, Morhart P, Smith R, Le Merrer M, Rogers JG, Connor JM, Kitterman JA. The phenotype of fibrodysplasia ossificans progressiva. **Clin Rev Bone Miner Metab** 3: 183-188, 2005

Mahboubi S, Glaser DL, Shore EM, Kaplan FS. Fibrodysplasia ossificans progressiva. **Pediatr Radiol** 31: 307-314, 2001

Reinig JW, Hill SC, Fang M, Marini J, Zasloff MA. Fibrodysplasia ossificans progressiva: CT appearance. **Radiology** 159: 153-157, 1986

### **E. Histopathology of FOP Lesions**

Gannon FH, Glaser D, Caron R, Thompson LDR, Shore EM, Kaplan FS. Mast cell involvement in fibrodysplasia ossificans progressiva (FOP). **Hum Pathol** 32: 842-848, 2001

Gannon FH, Valentine BA, Shore EM, Zasloff MA, Kaplan FS. Acute lymphocytic infiltration in an extremely early lesion of fibrodysplasia ossificans progressiva. **Clin Orthop** 346: 19-25, 1998

Hegyí L, Gannon FH, Glaser DL, Shore EM, Kaplan, FS, Shanahan CM. Stromal cells of fibrodysplasia ossificans progressiva lesions express smooth muscle lineage markers and the osteogenic transcription factor Runx2/Cbfa-1: Clues to a vascular origin of heterotopic ossification. **J Pathol** 201: 141-148, 2003.

Horwitz EM. Building bone from blood vessels. **Nat Med** 12: 1373-1374, 2010.

Kaplan FS, Glaser DL, Shore EM, Pignolo RJ, Xu M, Zhang Y, Senitzer D, Forman SJ, Emerson SG, Hematopoietic stem cell contribution to ectopic skeletogenesis. **J Bone Joint Surg** 347-357, 2007

Kaplan FS, Tabas J, Gannon FH, Finkel G, Hahn GV, Zasloff MA. The histopathology of fibrodysplasia ossificans progressiva: an endochondral process. **J Bone Joint Surg Am** 75-A: 220-230, 1993

Lounev VY, Ramachandran R, Wosczyzna MN, Yamamoto M, Maidment AD, Shore EM, Glaser DL, Goldhamer DJ, Kaplan FS. Identification of progenitor calls that contribute to heterotopic skeletogenesis. **J Bone Joint Surg Am** 91: 652-663, 2009.

Medici D, Shore EM, Lounev VY, Kaplan FS, Kalluri R, Olsen BR. Conversion of vascular endothelial cells into multipotent stem-like cells. **Nat Med** 12: 1400-1406, 2010

Pignolo RJ, Suda RK, Kaplan FS. The fibrodysplasia ossificans progressiva lesion. **Clin Rev Bone Miner Metab** 3: 195-200, 2005

Suda RK, Billings PC, Egan KP, Kim JH, McCarrick-Walmsley R, Glaser DL, Porter DL, Shore EM. Pignolo RJ. Circulating osteogenic precursor cells in heterotopic bone formation. **Stem Cells** 27: 2209-2219, 2009

## **F. Laboratory Findings in FOP**

Estrores IM, Harrington A, Banovae K. C-reactive protein and erythrocyte sedimentation rate in patients with heterotopic ossification after spinal cord injury. **J Spinal Cord Med** 27: 434-437, 2004

Kaplan FS, Sawyer J, Connors S, Keough K, Shore E, Gannon F, Glaser D, Rocke D, Zasloff M, Folkman J. Urinary basic fibroblast growth factor: a biochemical marker for preosseous fibroproliferative lesions in patients with FOP. **Clin Orthop** 346: 59-65, 1998

Lutwak, L. Myositis ossificans progressiva: mineral, metabolic & radioactive calcium studies of the effects of the hormones. **Am J Med** 37: 269-293, 1964

Suda RK, Billings PC, Egan KP, Kim JH, McCarrick-Walmsley R, Glaser DL, Porter DL, Shore EM. Pignolo RJ. Circulating osteogenic precursor cells in heterotopic bone formation. **Stem Cells** 27: 2209-2219, 2009

## **G. The Immune System & FOP**

Kaplan FS, Glaser DL, Shore EM, Pignolo RJ, Xu M, Zhang Y, Senitzer D, Forman SJ, Emerson SG. Hematopoietic stem-cell contribution to ectopic skeletogenesis. **J Bone Joint Surg Am** 89: 347-357, 2007

Kan L, Liu Y, McGuire TL, Berger DM, Awatramani RB, Dymecki SM, Kessler JA. Dysregulation of local stem/progenitor cells as a common cellular mechanism for heterotopic ossification. **Stem Cells** 27: 150-156, 2009

Kaplan FS, Shore EM, Gupta R, Billings PC, Glaser DL, Pignolo RJ, Graf D, Kamoun M. Immunological features of fibrodysplasia ossificans progressiva and the dysregulated BMP4 Pathway. **Clin Rev Bone Miner Metab** 3: 189-193, 2005

Lanchoney TF, Cohen RB, Rocke DM, Zasloff MA, Kaplan FS. Permanent heterotopic ossification at the injection site after diphtheria-tetanus-pertussis immunizations in children who have fibrodysplasia ossificans progressiva. **J Pediatrics** 126: 762-764, 1995

Lounev VY, Ramachandran R, Wosczyzna MN, Yamamoto M, Maidment AD, Shore EM, Glaser DL, Goldhamer DJ, Kaplan FS. Identification of progenitor cells that contribute to heterotopic skeletogenesis. **J Bone Joint Surg Am** 91: 652-663, 2009

Yu PB, Deng DY, Lai CS, Hong CC, Cuny GD, Boussein ML, Hong DW, McManus PM, Katagiri T, Sachidanandan C, Nobuhiro K, Fukuda T, Mishina Y, Peterson RT, Bloch KD. BMP type I receptor inhibition reduces heterotopic ossification. **Nat Med** 14, 1363-1369, 2008.

## **H. Misdiagnosis in FOP**

Kitterman JA, Kantanie S, Rocke DM, Kaplan FS. Iatrogenic harm caused by diagnostic errors in fibrodysplasia ossificans progressiva. **Pediatrics** 116: 654-661, 2005

Zaghloul KA, Heuer GG, Guttenberg MD, Shore EM, Kaplan FS, Storm PB. Lumbar puncture and surgical intervention in a child with undiagnosed fibrodysplasia ossificans progressiva. **J Neurosurg Pediatrics** 1: 91-94, 2008

## **I. Epidemiologic, Genetic & Environmental Factors in FOP**

Hebela N, Shore EM, Kaplan FS. Three pairs of monozygotic twins with fibrodysplasia ossificans progressiva: the role of environment in the progression of heterotopic ossification. **Clin Rev Bone Miner Metab** 3: 205-208, 2005

Janoff HB, Muenke M, Johnson LO, Rosenberg A, Shore EM, Okereke E, Zasloff M, Kaplan FS. Fibrodysplasia ossificans progressiva in two half-sisters: evidence for maternal mosaicism. **Am J Med Genetics** 61: 320-324, 1996

Janoff HB, Tabas JA, Shore EM, Muenke M, Dalinka MK, Schlesinger S, Zasloff MA, Kaplan FS. Mild expression of fibrodysplasia ossificans progressiva. **J Rheumatol** 22: 976-978, 1995

Morales-Piga A, Kaplan FS. Osteochondral diseases and fibrodysplasia ossificans progressiva. **Adv Exp Med Biol** 686: 335-348, 2010

Kaplan FS, McCluskey W, Hahn G, Tabas J, Muenke M, Zasloff MA. Genetic transmission of fibrodysplasia ossificans progressiva. **J Bone Joint Surg Am** 75: 1214-1220, 1993

Rogers JG, Chase GA. Paternal age effect in fibrodysplasia ossificans progressiva. **J Med Genet** 16: 147-148, 1979

Shore EM, Feldman GJ, Xu M, Kaplan FS. The genetics of fibrodysplasia ossificans progressiva. **Clin Rev Bone Miner Metab** 3: 201-204, 2005

Virdi AS, Shore EM, Oreffo RO, Li M, Connor JM, Smith R, Kaplan FS, Triffitt, JT. Phenotypic and molecular heterogeneity in fibrodysplasia ossificans progressiva. **Calcified Tissue Int** 65: 250-255, 1999

### **J. FOP & the BMP Signaling Pathway**

Ahn J, Serrano de la Peña L, Shore EM, Kaplan FS. Aresis of a bone morphogenetic protein – antagonist response in a genetic disorder of heterotopic skeletogenesis. **J Bone Joint Surg Am** 85: 667-674, 2003

Billings PC, Fiori JL, Bentwood JL, O’Connell MP, Jiao X, Nussbaum B, Caron RJ, Shore EM, Kaplan FS. Dysregulated BMP signaling and enhanced osteogenic differentiation of connective tissue progenitor cells from patients with fibrodysplasia ossificans progressiva. **J Bone Miner Res** 23: 305-313, 2008

Fiori JL, Billings PC, Serrano de la Peña L, Kaplan FS, Shore EM. Dysregulation of the BMP-p38 MAPK signaling pathway in cells from patients with fibrodysplasia ossificans progressiva. **J Bone Miner Res** 21: 902-909, 2006

Gannon FH, Kaplan FS, Olmsted E, Finkel G, Zasloff MA, Shore EM. Bone morphogenetic protein 2/4 in early fibromatous lesions of fibrodysplasia ossificans progressiva. **Hum Pathol** 28: 339-343, 1997

Glaser DL, Economides AN, Wang L, Liu X, Kimble RD, Fandl JP, Wilson JM, Stahl, N, Kaplan FS, Shore EM. In vivo somatic cell gene transfer of an engineered noggin mutein prevents BMP4-induced heterotopic ossification. **J Bone Joint Surg Am** 12: 2332-2342, 2003

Hegyi L, Gannon FH, Glaser DL, Shore EM, Kaplan FS, Shanahan CM. Stromal cells of fibrodysplasia ossificans progressiva lesions express smooth muscle lineage markers and the osteogenic transcription factor Runx2/Cbfa-1: Clues to a vascular origin of heterotopic ossification? **J Pathol** 201: 141-148, 2003

Kaplan FS, Groppe J, Pignolo RJ, Shore EM. Morphogen receptor genes and metamorphogenesis: skeleton keys to metamorphosis. **Ann NY Acad Sci** 1116: 113-133, 2007

Kaplan FS, Tabas JA, Zasloff MA. Fibrodysplasia ossificans progressiva: A clue from the fly? **Calcif Tiss Int** 47: 117-125, 1990

O’Connell MP, Billings PC, Fiori JL, Deirmengian G, Roach HI, Shore EM, Kaplan FS. HSPG modulation of BMP signaling in fibrodysplasia ossificans progressiva cells. **J Cell Biochem** 102: 1493-1503, 2007

Roush W. Protein builds second skeleton. **Science** 273: 1170, 1996

Serrano de la Peña L, Billings PC, Fiori JL, Ahn J, Shore EM, Kaplan FS. Fibrodysplasia ossificans progressiva (FOP), a disorder of ectopic osteogenesis, misregulates cell surface expression and trafficking of BMPRIA. **J Bone Miner Res** 20: 1168-1176, 2005

Shafritz AB, Shore EM, Gannon FH, Zasloff MA, Taub R, Muenke M, Kaplan FS. Overexpression of an osteogenic morphogen in fibrodysplasia ossificans progressiva (FOP). **N Engl J Med** 335: 555-561, 1996

Shen Q, Little SC, Xu M, Haupt J, Ast C, Katagiri T, Mundlos S, Seemann P, Kaplan FS, Mullins MC, Shore EM. The fibrodysplasia ossificans progressiva R20H ACVR1 mutation activates BMP-independent chondrogenesis and zebrafish embryo ventralization. **J Clin Invest** 119: 3462-3472, 2009

Shore EM, Xu M, Feldman GJ, Fenstermacher DA, Cho T-J, Choi IH, Connor JM, Delai P, Glaser DL, Le Merrer M, Morhart R, Rogers JG, Smith R, Triffitt JT, Urtizberea JA, Zasloff M, Brown MA, Kaplan FS. A recurrent mutation in the BMP type I receptor ACVR1 causes inherited and sporadic fibrodysplasia ossificans progressiva. **Nature Genetics** 38: 525-527, 2006

## K. The FOP Gene

Bocciardi R, Bordo D, DiDuca M, DiRocco M, Ravazzolo R. Mutational analysis of the ACVR1 gene in Italian patients affected with fibrodysplasia ossificans progressiva: confirmations and advancements. **Eur J Hum Genet** 17: 311-318, 2009

Couzin J. Bone disease gene finally found. **Science** 312: 514-515, 2006

Furuya H, Ikezoe K, Wang L, Ohyagi Y, Motomura K, Fujii N, Kira J, Fukumaki Y. A unique case of fibrodysplasia ossificans progressiva with an ACVR1 mutation, G356D, other than the common mutation. (R206H). **Am J Med Genet A** 146: 459-463, 2008

Gregson CL, Hollingsworth P, Williams M, Petrie KA, Bullock AN, Brown MA, Tobias JH, Triffitt JT. A novel ACVR1 mutation in the glycine/serine-rich domain found in the most benign case of a fibrodysplasia ossificans progressiva variant reported to date. **Bone** [Epub ahead of print] 2010.

Kaplan FS. The key to the closet is the key to the kingdom: a common lesson of rare diseases. **Orphan Disease Update** 24(3): 1-9, 2006

Kaplan FS, Groppe J, Pignolo RJ, Shore EM. Morphogen receptor genes and metamorphogenesis: skeleton keys to metamorphosis. **Ann NY Acad Sci** 1116: 113-133, 2007

Kaplan FS, Xu M, Seemann P, Connor M, Glaser DL, Carroll L, Delai P, Fastnacht-Urban E, Forman SJ, Gillessen-Kaesbach G, Hoover-Fong J, Köster B, Morhart R, Pauli RM, Reardon W, Zaidi SA, Zasloff M, Mundlos S, Groppe J, Shore EM. Classical and atypical FOP phenotypes are caused by mutations in the BMP type I receptor ACVR1. **Human Mutation** 30: 379-390, 2009

Petrie KA, Lee WH, Bullock AN, Pointon JJ, Smith R, Russell RG, Brown MA, Wordsworth BP, Triffitt JT. Novel mutations in ACVR1 result in atypical features in two fibrodysplasia ossificans progressiva patients. **PLoS One** 4(3): e5005, 2009



Shore EM, Kaplan FS. Insights from a rare genetic disorder of extra-skeletal bone formation, fibrodysplasia ossificans progressiva. **Bone** 43: 427-433, 2008

Shore EM, Kaplan FS. Inherited human disease of heterotopic bone formation. **Nat Rev Rheumatol** 6: 518-527, 2010

Shore EM, Xu M, Feldman GJ, Fenstermacher DA, Cho T-J, Choi IH, Connor JM, Delai P, Glaser DL, Le Merrer M, Morhart R, Rogers JG, Smith R, Triffitt JT, Urtizberea JA, Zasloff M, Brown MA, Kaplan FS. A recurrent mutation in the BMP type I receptor ACVR1 causes inherited and sporadic fibrodysplasia ossificans progressiva. **Nature Genetics** 38: 525-527, 2006

Xu M-Q, Feldman G, Le Merrer M, Shugart YY, Glaser DL, Urtizberea JA, Fardeau M, Connor JM, Triffitt J, Smith R, Shore EM, Kaplan FS. Linkage exclusion and mutational analysis of the noggin gene in patients with fibrodysplasia ossificans progressiva. **Clin Genet** 58: 291-298, 2000

## **L. Structural and Functional Consequences of the FOP Mutation**

Chen Y-G, Liu F, Massagué J. Mechanism of TGF- $\beta$  receptor inhibition by FKBP12. **The EMBO J** 16: 3866-3876. 1997

Fukuda T, Kohda M, Kanomata K, Nojima J, Nakamura A, Kamizono J, et al. Constitutively activated ALK2 and increased SMAD 1/5 cooperatively induce bone morphogenetic protein signaling in fibrodysplasia ossificans progressiva. **J Biol Chem**. 284: 7149-7156, 2009

Groppe JC, Shore EM, Kaplan FS. Functional modeling of the ACVR1 (R206H) mutation in FOP. **Clin Orthop Relat Res** 462: 87-92, 2007

Groppe JC, Wu J, Shore EM, Kaplan FS. *In vitro* analysis of the dysregulated R206H ALK2 kinase – FKBP12 interaction associated with heterotopic ossification in FOP. **Cells Tissues Organs**, in press, 2011

Kaplan FS, Groppe J, Pignolo RJ, Shore EM. Morphogen receptor genes and metamorphogens: skeleton keys to metamorphosis. **Ann NY Acad Sci** 1116: 113-133, 2007

Kaplan FS, Pignolo RJ, Shore EM. The FOP metamorphogene encodes a novel type I receptor that dysregulates BMP signaling. **Cytokine Growth Factor Rev** 20: 399-407, 2009

Kaplan FS, Shen Q, Lounev V, Seemann P, Groppe J, Katagiri T, Pignolo RJ, Shore EM. Skeletal metamorphosis in fibrodysplasia ossificans progressiva. **J Bone Miner Metab** 26: 521-530, 2008

Shen Q, Xu M, Little SC, Kaplan FS, Mullins MC, Shore EM. Activation of BMP signaling by the FOP ACVR1 R206H mutation. **J Bone Miner Res** 22 (suppl. 1): S43, 2009

Shen Q, Little SC, Xu M, Haupt J, Ast C, Katagiri T, Mundlos S, Seemann P, Kaplan FS, Mullins MC, Shore EM. The fibrodysplasia ossificans progressiva R20H ACVR1 mutation activates BMP-independent chondrogenesis and zebrafish embargo ventralization. **J Clin Invest** 119: 3462-3472, 2009

Shore EM, Xu M, Feldman GJ, Fenstermacher DA, Cho T-J, Choi IH, Connor JM, Delai P, Glaser DL, Le Merrer M, Morhart R, Rogers JG, Smith R, Triffitt JT, Urtizberea JA, Zasloff M, Brown MA, Kaplan FS. A recurrent mutation in the BMP type I receptor ACVR1 causes inherited and sporadic fibrodysplasia ossificans progressiva. **Nature Genetics** 38: 525-527, 2006

Song GA, Kim HJ, Woo KM, Baek JH, Kim GS, Choi JY, Ryoo HM. Molecular consequences of the ACVR1 R206H mutation of fibrodysplasia ossificans progressiva. **J Biol Chem** May 12, 2010 (Epub ahead of print).

van Dinther M, Visser N, de Gorter DJJ, Doorn J, Goumans M-J, de Boer J, ten Dijke P. ALK2 R206H mutation linked to fibrodysplasia ossificans progressiva confers constitutive activity to the BMP type I receptor and sensitizes mesenchymal cells to BMP-induced osteoblast differentiation and bone formation. **J Bone Miner Res** 25: 1208-1215, 2010

Wang T, Li B-Y, Danielson PD, Shah PC, Rockwell, S, Lechleider RJ, Martin J, Manganaro T, Donahoe PK. The immunophilin FKBP12 functions as a common inhibitor of the TGF- $\beta$  family type I receptors. **Cell** 86: 435-444, 1996

Yamaguchi T, Kurisaki A, Yamakawa N, Minakuchi K, Sugino H. FKBP12 functions as an adaptor of the Smad7-Smurfl complex on activin type I receptor. **J Mol Endocrinol** 36: 569-579, 2006

## **M. Genetic Testing & FOP**

Kaplan FS, Xu M, Glaser DL, Collins F, Connor M, Kitterman J, Sillence D, Zackai E, Ravitsky V, Zasloff M, Ganguly A, Shore EM. Early diagnosis of fibrodysplasia ossificans progressiva. **Pediatrics** 121: e1295-e1300, 2008.

## **N. Animal Models of FOP**

Chakkalakal SA, Zhang D, Culbert A, Wright AC, Maidment ADA, Kaplan FS, Shore EM. The ACVR1 R206H mutation recapitulates the clinical phenotype of FOP in a knock-in mouse model. **J Bone Miner Res** 25: s4, 2010.

Chakkalakal SA, Zhang D, Raabe T, Richa J, Hankenson K, Kaplan FS, Shore EM. ACVR1 knock-in mouse model for fibrodysplasia ossificans progressiva. **J Bone Miner Res** 23: s57, 2008.

Fukada T, Scott G, Komatsu Y, Araya R, Kawano M, Ray, MK, Yamada M, Mishina Y. Generation of a mouse with conditionally activated signaling through the BMP receptor, ALK2. **Genesis** 44: 159-167, 2006

Glaser DL, Economides AN, Wang L, Liu X, Kimble RD, Fandl JP, Wilson JM, Stahl, N, Kaplan FS, Shore EM. In vivo somatic cell gene transfer of an engineered noggin mutein prevents BMP4-induced heterotopic ossification. **J Bone Joint Surg Am** 12: 2332-2342, 2003

Kan L, Hu M, Gomes WA, Kessler JA. Transgenic mice overexpressing BMP4 develop a fibrodysplasia ossificans progressiva (FOP)-like phenotype. **Am J Pathol** 165: 1107-1115, 2004

Kan L, Liu Y, McGuire TL, Berger DM, Awatramani RB, Dymecki SM, Kessler JA. Dysregulation of local stem/progenitor cells as a common cellular mechanism for heterotopic ossification. **Stem Cells** 27: 150-156, 2009

Kaplan FS, Shore EM, Pignolo RJ, Glaser DL. Animal models of fibrodysplasia ossificans progressiva. **Clin Rev Bone Miner Metab** 3: 229-234, 2005

Lounev VY, Ramachandran R, Wosczyzna MN, Yamamoto M, Maidment AO, Shore EM, Glaser DL, Goldhamer DJ, Kaplan FS. Identification of progenitor cells that contribute to heterotopic skeletogenesis. **J Bone Joint Surg Am** 91: 652-663, 2009

Olmsted EA, Gannon FH, Wang Z-Q, Grigoriadis AE, Wagner EF, Zasloff MA, Shore EM, Kaplan FS. Embryonic overexpression of the c-fos proto-oncogene: a murine stem cell chimera applicable to the study of fibrodysplasia ossificans progressiva in humans. **Clin Orthop** 346: 81-94, 1998

Shen Q, Little SC, Xu M, Haupt J, Ast C, Katagiri T, Mundlos S, Seemann P, Kaplan FS, Mullins MC, Shore EM. The fibrodysplasia ossificans progressiva R206H ACVR1 mutation activates BMP independent chondrogenesis and zebrafish embryo ventralization. **J Clin Invest** 119: 3462-3472, 2009.

## **O. Challenges of Therapeutic Assessment in FOP**

Auerbach AD, Landefeld CS, Shojania KG. The tension between needing to improve care and knowing how to do it. **N Engl J Med** 357: 608-613, 2007

Hellman S, Hellman DS. Of mice but not men: problems of the randomized clinical trial. **New Engl J Med** 324: 1585-1589, 1991

Kaplan FS, Groppe J, Shore EM. When one skeleton is enough: approaches and strategies of the treatment of fibrodysplasia ossificans progressiva. **Drug Discovery Today: Therapeutic Strategies** 5: 255-262, 2009.

Kaplan FS, Glaser DL, Pignolo RJ, Shore EM. A new era for fibrodysplasia ossificans progressiva: a druggable target for the second skeleton. **Expert Opin Biol Ther** 7: 705-712, 2007

Kaplan FS, Le Merrer M, Glaser DL, Pignolo RJ, Goldsby R, Kitterman JA, Groppe J, Shore EM. Fibrodysplasia ossificans progressiva (FOP). **Best Practice & Research – Clinical Rheumatology** 22: 191-205, 2008

Miller FG, Rosenstein DL. The therapeutic orientation to clinical trials. **N Engl J Med** 348: 1383-1386, 2003

Passamani E. Clinical trials - are they ethical? **New Engl J Med** 324: 1589-1591, 1991

Rosenstirn J. A contribution to the study of myositis ossificans progressiva. **Ann Surg** 68: 485-520, 591-637, 1918

Stephens T, Brynner R: **Dark Remedy**. The Impact of Thalidomide And Its Revival as a Vital Medicine. Perseus Books, 208 pages, 2001

Yu PB, Deng DY, Lai CS, Hong CC, Cuny GD, Buxsein ML, Hong DW, McManus PM, Katagiri T, Sachidanandan C, Nobuhiro K, Fukuda T, Mishina Y, Peterson RT, Bloch KD. BMP type I receptor inhibition reduces heterotopic ossification. **Nat Med** 14, 1363-1369, 2008.

## II. THE PATHOLOGIC AND PATHOPHYSIOLOGIC-BASED TREATMENT OF FOP

### A. Introduction

Glaser DL, Kaplan FS. Treatment considerations for the management of fibrodysplasia ossificans progressiva. **Clin Rev Bone Miner Metab** 3: 243-250. 2005

Kaplan FS, Le Merrer M, Glaser DL, Pignolo RJ, Goldsby R, Kitterman JA, Groppe J, Shore EM. Fibrodysplasia ossificans progressiva (FOP). **Best Practice & Research – Clinical Rheumatology** 22: 191-205, 2008

### B. Corticosteroids

Janoff HB, Zasloff MA, Kaplan FS. Submandibular swelling in patients with fibrodysplasia ossificans progressiva. **Otolaryngol Head Neck Surg** 114: 599-604, 1996

Kaplan FS, Glaser DL, Shore EM, Pignolo RJ, Xu M, Zhang Y, Senitzer D, Forman SJ, Emerson SG. Hematopoietic stem-cell contribution to ectopic skeletogenesis. **J Bone Joint Surg Am** 89: 347-357, 2007

Lounev VY, Ramachandran R, Wosczyzna MN, Yamamoto M, Maidment AD, Shore EM, Glaser DL, Goldhamer DJ, Kaplan FS. Identification of progenitor cells that contribute to heterotopic skeletogenesis. **J Bone Joint Surg Am** 91: 652-663, 2009

Rhen T & Cidlowski JA. Anti-inflammatory action of glucocorticoids – new mechanisms for old drugs. **N Engl J Med** 353: 1711-1723, 2005

Staa TPV, Cooper C, Leufkens HGM, Bishop N. Children and the risk of fractures caused by oral corticosteroids. **J Bone Miner Res** 18: 913-918, 2003

Yu PB, Deng DY, Lai CS, Hong CC, Cuny GD, Boussein ML, Hong DW, McManus PM, Katagiri T, Sachidanandan C, Nobuhiro K, Fukuda T, Mishina Y, Peterson RT, Bloch KD. BMP type I receptor inhibition reduces heterotopic ossification. **Nat Med** 14, 1363-1369, 2008.

### C. Mast Cell Inhibitors

Gannon FH, Glaser D, Caron R, Thompson LDR, Shore EM, Kaplan FS. Mast cell involvement in fibrodysplasia ossificans progressiva. **Hum Pathol** 32: 842-848, 2001

Kaplan AP. Chronic urticaria and angioedema. **N Engl J Med** 346:175-179, 2002

Simmons FER. Advances in H<sub>1</sub> –Antihistamines. **N Engl J Med** 351:2203-2217, 2004

#### D. Cyclo-oxygenase 2 inhibitors & NSAIDs

Deeks JJ, Smith LA, Bradley MD. Efficacy, tolerability, and upper gastrointestinal safety of celecoxib for treatment of osteoarthritis and rheumatoid arthritis: systematic review of randomized controlled trials. **British Med J** (Review) 325: 619, 2002

DiCesare PE, Nimni ME, Pen L, Yazdi M, Cheung DT. Effects of Indomethacin on demineralized bone-induced heterotopic ossification in the rat. **J Orthop Res** 9: 855-861, 1991

Fitzgerald GA. Coxibs and cardiovascular disease. **N Engl J Med** 351: 1709-1711, 2004

Grosser T, Fries S, Fitzgerald GA. Biological basis for the cardiovascular consequences of cox-2 inhibition: therapeutic challenges and opportunities. **J Clin Invest** 116: 4-15, 2006

Jones, MK, Wang H, Peskar BM, Levin E, Itani RM Sarfeh IJ, Tarnawski AS. Inhibition of angiogenesis by nonsteroidal anti-inflammatory drugs: insight into mechanisms and implications for cancer growth and ulcer healing. **Nature Med** 5: 1418-1423, 1999

Katori M, Majima M. Cyclooxygenase-2: its rich diversity of roles and possible application of its selective inhibitors. **Inflammation Res** 49: 367-392, 2000

Levitz CL, Cohen RB, Zasloff MA, Kaplan FS. The role of prostaglandins in bone formation. Abstracts from The First International Symposium on Fibrodysplasia Ossificans Progressiva, September 25-26, 1991, Philadelphia, Pennsylvania. **Calcif Tissue Int** 50: 385-388, 1992

Merck & Co: Merck announces voluntary worldwide withdrawal of Vioxx. [www.merck.com](http://www.merck.com). September 30, 2004

Simon AM, Manigrasso MB, O'Connor JP. Cyclo-oxygenase 2 function is essential for bone fracture healing. **J Bone Miner Res** 17: 963-976, 2002

Stempak D, Gammon J, Klein J, Koren G, Baruchel S. Single-dose and steady-state pharmacokinetics of celecoxib in children. **Clin Pharmacol Ther** 72: 490-497, 2002

Topol EJ. Failing the public health – rofecoxib, Merck, and the FDA. **N Engl J Med** 351:1707-1709, 2004

Van Ryn J, Pairet M: Clinical experience with cyclooxygenase-2 inhibitors. **Inflammation Res.** 48: 247-254, 2000

Weinreb M, Suponitsky I, Keila S. Systemic administration of an anabolic dose of PGE2 in young rats increases the osteogenic capacity of bone marrow. **Bone** 20: 521-526, 1997

White WB, Faich G, Borer JS, Makuch RW. Cardiovascular thrombotic events in arthritis trials of the cyclooxygenase-2 inhibitor celecoxib **Am J Cardiol** 92: 411-418, 2003

White WB, Faich G, Whelton A, Maurath C, Ridge NJ, Verburg KM, Geis GS, Lefkowitz JB. Comparison of thromboembolic events in patients treated with celecoxib, a cyclooxygenase-2 specific inhibitor, versus ibuprofen or diclofenac. **Am J Cardiol** 89: 425-430, 2002

Zhang X, Schwarz EM, Young DA, Puzas E, Rosier RN, O’Keefe RJ. Cyclo-oxygenase-2 regulates mesenchymal cell differentiation into the osteoblast lineage and is critically involved in bone repair. **J Clin Invest** 109: 1405-1415, 2002

## **E. Aminobisphosphonates**

Bilezikian JP. Osteonecrosis of the jaw – do bisphosphonates pose a risk? **N Engl J Med** 355: 2278-2281, 2006

Black DM, Delmas PD, Eastell R, Reid IR, Boonen S, Cauley JA, Cosman F, Lakatos P, Leung PC, Man Z, Mautalen C, Mesenbrink P, Hu H, Caminis J, Tong K, Rosario-Jansen T, Krasnow J, Hue TF, Sellmeyer D, Eriksen EF, Cummings SR. Horizon Pivotal Fracture Trial. Once yearly zoledronic acid for treatment of postmenopausal osteoporosis. **N Engl J Med** 356: 1809-1822, 2007

Black DM, Kelly MP, Genant HK, Palermo L, Eastell R, Bucci-Rechtweg, Cauley J, Leung PC, Boonen S, Santora A, de Papp A, Bauer DC. Bisphosphonates and fractures of the subtrochanteric or diaphyseal femur. **N Engl J Med** 362: 1761-1771, 2010

Brantus JF, Meunier PJ. Effects of intravenous etidronate and oral corticosteroids in fibrodysplasia ossificans progressiva. **Clin Orthop** 346: 117-120, 1998

Brumsen C, Hamdy NAT, Papapoulos SE. Long-term effects of bisphosphonates on the growing skeleton (studies of young patients with severe osteoporosis). **Medicine** 76: 266-283, 1997

Body JJ. Dosing regimens and main adverse events of bisphosphonates. **Semin Oncol** (4 supplement 11): 49-53, 2001

Capeci CM, Tejawani MD. Bilateral low-energy simultaneous or sequential femoral fractures in patients on long-term alendronate therapy. **J Bone Joint Surg Am** 91: 2556-2561, 2009

DiMeglio LA, Peacock M. Two-year clinical trial of oral alendronate versus intravenous pamidronate in children with osteogenesis imperfecta. **J Bone Miner Res** 21: 132-140, 2006

Dunford JE, Thompson K, Coxon FP, Luckman SP, Hahn FM, Poulter CD, Ebetino FH, Rogers MJ. Structure-activity relationships for inhibition of farnesyl diphosphate synthase in vitro and inhibition of bone resorption in vivo by nitrogen-containing bisphosphonates. **J Pharmacol Exp Therap** 296: 235-242, 2001

Falk MJ, Heeger S, Lynch KA, DeCaro KR, Bohach D, Gibson KS, Warman ML. Intravenous bisphosphonate therapy in children with osteogenesis imperfecta. **Pediatrics** 111: 573-578, 2003

Fournier P, Boissier S, Filleur S, Guglielmi J, Cabon F, Colombel M, Clezardin P. Bisphosphonates inhibit angiogenesis in vitro and testosterone-stimulated vascular regrowth in the ventral prostate in castrated rats. **Cancer Res** 62: 6538-6544, 2002

Green JR. Preclinical pharmacology of zoledronic acid. **Semin Oncol** 29 (6 suppl. 21): 3-11, 2002

Green JR. Antitumor effects of bisphosphonates. **Cancer** 97 (supplement): 840-847, 2003

- Hasmim M, Bieler G, Rüegg C. Zoledronate inhibits endothelial cell adhesion, migration and survival through the suppression of multiple, prenylation-dependent signaling pathways. **J Throm Haemost** 5: 166-173, 2007
- Hiraoka K, Zenmyo M, Watari K, Iguchi H, Fotovati A, Kimura YN, Hosoi F, Shoda T, Nagata K, Osada H, Ono M, Kuwano M. Inhibition of bone and muscle metastases of lung cancer cells by a decrease in number of monocytes/macrophages. **Cancer Sci** 99: 1595-1602, 2008
- Idris AI, Rojas J, Greig IR, Van't Hof RJ, Ralston SH. Aminobisphosphonates cause osteoblast apoptosis and inhibit bone nodule formation in vitro. **Calcif Tissue Int** 82: 191-201, 2008
- Kan L, Liu Y, McGuire TL, Berger DM, Awatramani RB, Dymecki SM, Kessler JA. Dysregulation of local stem/progenitor cells as a common cellular mechanism for heterotopic ossification. **Stem Cells** 27: 150-156, 2009
- Khosla S, Burr D, Cauley J, Dempster DW, Ebeling PR, Felsenberg D, Gagel RF, Gilsanz V, Guise T, Koka S, McCauley LK, McGowan J, McKee MD, Mohla S, Pendrys DG, Raisz LG, Ruggiero SL, Shafer DM, Shum L, Silverman SL, Van Poznak CH, Watts N, Woo SB, Shane E. Bisphosphonate-associated osteonecrosis of the jaw: report of a task force of The American Society for Bone and Mineral Research. **J Bone Miner Res** 22: 1479-1491, 2007
- Marini JC. Do bisphosphonates make children's bones better or brittle? **New Engl J Med** 349:423-426, 2003
- Munns CFJ, Rauch F, Zeitlin L, Fassier F, Glorieux FH. Delayed osteotomy but not fracture healing in pediatric osteogenesis imperfecta patients receiving pamidronate. **J Bone Min Res** 19: 1779-1786, 2004
- Nogginuera A, Ros JB, Pavia C, Alcover E, Valls C, Villaronga M, Gonzalez E. Bisphosphonates, a new treatment for glucocorticoid-induced osteoporosis in children. **J Pediatr Endocrinol Metab** 16: 529-536, 2003
- Orcel P, Beaudreuil J. Bisphosphonates in bone disease other than osteoporosis. **Joint Bone Spine** 69: 19-27, 2002
- Pecherstorfer M, Jilch R, Sauty A, Horn E, Keck AV, Zimmer-Roth I, Thiebaud D. Effect of first treatment with aminobisphosphonates pamidronate and ibandronate on circulating lymphocyte subpopulations. **J Bone Miner Res** 15: 147-154, 2000
- Rauch F, Plotkin H, Zeitlin L, Glorieux FH. Bone mass, size, and density in children and adolescents with osteogenesis imperfecta: effect of intravenous pamidronate therapy. **J Bone Miner Res** 18: 610-614, 2003
- Rauch F, Travers R, Plotkin H, Glorieux FH. The effects of intravenous pamidronate on the bone tissue of children and adolescents with osteogenesis imperfecta. **J Clin Invest** 110: 1293-1299, 2002
- Rosen CJ, Brown S. Severe hypocalcemia after intravenous bisphosphonate therapy in occult vitamin D deficiency. **N Engl J Med** 348: 1503-1504, 2003



Sambrook PN, Kotowicz M, Nash P, Styles CB, Naganathan V, Henderson-Briffa KN, Eisman JA, Nicholson GC. Prevention and treatment of glucocorticoid-induced osteoporosis: a comparison of calcitriol, vitamin D plus calcium, and alendronate plus calcium. **J Bone Miner Res** 18: 919-924, 2003

Santini D, Vincenzi B, Avvisati G, Dicuonzo G, Battistoni F, Gavasci M, Salerno A, Denaro V, Tonini G. Pamidronate induces modifications of circulating angiogenetic factors in cancer patients. **Clin Cancer Res**: 8: 1080-1084, 2002

Schuetz P, Mueller B, Christ-Crain M, Dick W, Haas H. Amino-bisphosphonates in heterotopic ossification: first experience in five consecutive cases. **Spinal Cord** 43: 604-610, 2005

Shane E. Evolving data about subtrochanteric fractures and bisphosphonates. **N Engl J Med** 362: 1825-1827, 2010

Staa TPV, Cooper C, Leufkens HGM, Bishop N. Children and the risk of fractures caused by oral corticosteroids. **J Bone Miner Res** 18: 913-918, 2003

Still K, Phipps RJ, Scutt A. Effects of risedronate, alendronate, and etidronate on the viability and activity of rat bone marrow stromal cells in vitro. **Calcif Tissue Int** 72: 143-150, 2003

Tassone P, Forciniti, S, Galea E, Morrone G, Turco MC, Martinelli V, Tagliaferri P, Venuta S. Growth inhibition and synergistic induction of apoptosis by zoledronate and dexamethasone in human myeloma cell lines. **Leukemia** 14: 841-844, 2000

Whyte MP, Wenkert D, Clements KL, McAlister WH, Mumm S. Bisphosphonate-induced osteopetrosis. **N Engl J Med** 349: 457-463, 2003

Wood J, Bonjean K, Ruetz S, Bellahcene A, Devy L, Foidart JM, Castronovo V, Green JR. Novel antiangiogenic effects of the bisphosphonate compound zoledronic acid. **J Pharmacol Exp Therap** 302: 1055-1061, 2002

Yamada J, Tsuno NH, Kitayama J, Tsuchiya T, Yoneyama S, Asakage M, Okaji Y, Nishikawa T, Tanaka J, Takahashi K, Nagawa H. Anti-angiogenic property of zoledronic acid by inhibition of endothelial progenitor cell differentiation. **J Surg Res** 151: 115-120, 2009

## **F. Acute & Chronic Pain Management in FOP**

Kaplan FS, Le Merrer M, Glaser DL, Pignolo RJ, Goldsby R, Kitterman JA, Groppe J, Shore EM. Fibrodysplasia ossificans progressiva (FOP). **Best Practice & Research – Clinical Rheumatology** 22: 191-205, 2008

## **G. Muscle Relaxants**

Glaser DL, Kaplan FS. Treatment considerations for the management of fibrodysplasia ossificans progressiva. **Clin Rev Bone Miner Metab** 3: 243-250. 2005

## **H. Chemotherapy Agents & Radiation Therapy**

Glaser DL, Kaplan FS. Treatment considerations for the management of fibrodysplasia ossificans progressiva. **Clin Rev Bone Miner Metab** 3: 243-250. 2005

Kaplan FS, Le Merrer M, Glaser DL, Pignolo RJ, Goldsby R, Kitterman JA, Groppe J, Shore EM. Fibrodysplasia ossificans progressiva (FOP). **Best Practice & Research – Clinical Rheumatology** 22: 191-205, 2008

## **I. Bone Marrow Transplantation**

Kaplan FS, Glaser DL, Shore EM, Pignolo RJ, Xu M, Zhang Y, Senitzer D, Forman SJ, Emerson SG. Hematopoietic stem-cell contribution to ectopic skeletogenesis. **J Bone Joint Surg Am** 89: 347-357, 2007

## **J. Rosiglitazone**

Gatti D, Viapiana O, Rossini M, Silvano A. Rosiglitazone therapy is associated with major clinical improvements in a patient with fibrodysplasia ossificans progressiva. **J Bone Miner Res** 25:1460-1462, 2010

Hong CC, Yu PB. Applications of small molecule BMP inhibitors in physiology and disease. **Cytokine Growth Factor Rev** 20:409-418, 2010

Kaplan FS (corresponding author) for the International Clinical Consortium on FOP. The medical management of fibrodysplasia ossificans progressiva: current treatment considerations. **Clin Proc Intl Clin Consort FOP** 3: 1-82, 2008

Kaplan FS, LeMerrer M, Glaser DL, Pignolo RJ, Goldsby RE, Kitterman JA, Groppe J, Shore EM. Fibrodysplasia ossificans progressiva. **Best Pract Res Clin Rheumatol** 22: 191-205, 2008

Kaplan FS, Pignolo RJ, Shore EM. Viewing FOP through rosi-colored glasses. **J Bone Miner Res** 25: 2295-2296, 2010

McDonough AK, Rosenthal RS, Cao X, Saag KG. The effect of thiazolidenediones on BMD and osteoporosis. **Nat Clin Pract Endocrinol Metab** 4: 507-513, 2008

Meier C, Kraenzlin ME, Bodmer M, Jick SS, Jick H, Meier CR. Use of thiazolidenedione and fracture risk. **Arch Intern Med** 168: 820-825, 2008

Nissen SE, Wolski K. Effect of rosiglitazone on the risk of myocardial infarction and death from cardiovascular causes. **N Engl J Med** 356: 2457-2471, 2007

Oakes ND, Kennedy CJ, Jenkins AB, Laybutt DR, Chisolm DJ, Kraegen EW. A new antidiabetic agent, BRL 49653 (rosiglitazone), reduces lipid availability and improves insulin action and glucoregulation in the rat. **Diabetes** 43: 1203-1210, 1994

Rosenstirn JA. A contribution to the study of myositis ossificans progressiva. **Ann Surg** 68: 468-520, 591-637, 1918

Shore EM, Xu M, Feldman GJ, Fenstermacher DA, Cho T-J, Choi IH, Connor JM, Delai P, Glaser DL, Le Merrer M, Morhart R, Rogers JG, Smith R, Triffitt JT, Urtizberea JA, Zasloff M, Brown MA, Kaplan FS. A recurrent mutation in the BMP type I receptor ACVR1 causes inherited and sporadic fibrodysplasia ossificans progressiva. **Nature Genetics** 38: 525-527, 2006

## **K. Retinoic Acid Receptor Agonists**

Kaplan FS, Shore EM. Derailing heterotopic ossification and RARing to go. **Nat Med** 17: 420-421, 2011

Shimono K, Morrison TN, Tung W, Chandraratna RA, Williams JA, Iwamoto M, Pacifici M. Inhibition of ectopic bone formation by a selective retinoic acid receptor  $\alpha$ -agonist: A new therapy for heterotopic ossification? **J Ortho Res** 28, 271-277, 2010

Shimono K, Tung W-e, Macolino C, Chi A, Didizian JH, Mundy C, Chandraratna RA, Mishina Y, Enomoto-Iwamoto M, Pacifici M, Iwamoto M. Potent inhibition of heterotopic ossification by nuclear retinoic acid receptor- $\gamma$  agonists. **Nat Med** 17: 454-460, 2011

Zasloff MA, Rocke DM, Crofford LJ, Hahn GV, Kaplan FS. Treatment of patients who have fibrodysplasia ossificans progressiva with isotretinoin. **Clin Orthop** 346: 121-129, 1998

## **L. Miscellaneous Agents**

Benetos IS, Mavrogenis AF, Themistocleous GS, Kanellopoulos AD, Papagelopoulos PJ, Soucacos PN. Optimal treatment of fibrodysplasia ossificans progressiva with surgical excision of heterotopic bone, indomethacin, and irradiation. **J Surg Orthop Adv** 15: 99-104, 2006

Gatti D, Viapiana O, Rossini M, Silvano A. Rosiglitazone therapy is associated with major clinical improvements in a patient with fibrodysplasia ossificans progressiva. **J Bone Miner Res**. November 2009 [Epub ahead of print]

Kaplan FS, Pignolo RJ, Shore EM. Viewing FOP Through Rosi-Colored Glasses. (An Editorial). Pp. 1-15. **IFOPA website**. [www.ifopa.org](http://www.ifopa.org), 2009

Moore, SE, Jump A, Smiley JD. Effect of warfarin sodium therapy on excretion of 4-carboxy-L-glutamic acid in scleroderma, dermatomyositis, and myositis ossificans progressiva. **Arthritis Rheum** 29: 344-351, 1986

Olsen NJ, Stein CM. New drugs for rheumatoid arthritis. **N Engl J Med** 350: 2167-2179, 2004

Wieder DL. Treatment of traumatic myositis ossificans with acetic acid iontophoresis. **Phys Ther** 72: 133-137, 1992

## M. Targeting ACVR1/ALK2: Definitive Targets for Therapy

Cuny GD, Yu PB, Laha JK, Xing X, Liu J-F, Lai CS, Deng DY, Sachidanandan C, Bloch KD, Peterson RT. Structure-activity relationship study of bone morphogenetic protein (BMP) signaling inhibitors. **Bioorganic & Medicinal Chemistry Letters**, 18: 4388-4392, 2008

Fukada T, Kohda M, Kanomata K, Nojima J, Kamizono J, Oda H, Nakayama K, Ohtake A, Miyazono K, Jimi E, Owan I, Okazaki Y, Katagiri T. A constitutively activated BMP receptor, ALK2, induces heterotopic bone formation in patients with fibrodysplasia ossificans progressiva. **J Bone Miner Res** 22 (suppl. 1); S10, 2007

Hong CC, Yu PB, Application of small molecules BMP inhibitors in physiology and disease. **Cytokines Growth Factor Rev** 20: 409-418, 2009

Kaplan FS. The key to the closet is the key to the kingdom: a common lesson of rare diseases. **Orphan Disease Update** 24(3): 1-9, 2006

Kaplan FS, Glaser DL, Pignolo RJ, Shore EM. A new era for fibrodysplasia ossificans progressiva: a druggable target for the second skeleton. **Expert Opin Biol Ther** 7: 705-712, 2007

Kaplan FS, Groppe J, Shore EM. When one skeleton is enough: approaches and strategies for the treatment of fibrodysplasia ossificans progressiva. **Drug Discovery Today: Therapeutic Strategies**. 5: 255-262, 2009

Kaplan FS, Le Merrer M, Glaser DL, Pignolo RJ, Goldsby R, Kitterman JA, Groppe J, Shore EM. Fibrodysplasia ossificans progressiva (FOP). **Best Practice & Research – Clinical Rheumatology** 22: 191-205, 2008

Kaplan FS, Pignolo R, Glaser DL, Shore EM. The Twentieth Annual FOP Collaborative Research Report. [www.ifopa.org](http://www.ifopa.org), 2011

Kaplan FS, Shore EM. Derailing heterotopic ossification and RARing to go. **Nat Med** 17: 420-421, 2011

Roush W. Protein builds second skeleton. **Science** 273: 1170, 1996

Shimono K, Tung W-e, Macolino C, Chi A, Didizian JH, Mundy C, Chandraratna RA, Mishina Y, Enomoto-Iwamoto M, Pacifici M, Iwamoto M. Potent inhibition of heterotopic ossification by nuclear retinoic acid receptor- $\gamma$  agonists. **Nat Med** 17: 454-460, 2011

Shore EM, Xu M, Feldman GJ, Fenstermacher DA, Cho T-J, Choi IH, Connor JM, Delai P, Glaser DL, Le Merrer M, Morhart R, Rogers JG, Smith R, Triffitt JT, Urtizberea JA, Zasloff M, Brown MA, Kaplan FS. A recurrent mutation in the BMP type I receptor ACVR1 causes inherited and sporadic fibrodysplasia ossificans progressiva. **Nature Genetics** 38: 525-527, 2006

Shen Q, Xu M, Little SC, Kaplan FS, Mullins MC, Shore EM. Activation of BMP signaling by the FOP ACVR1 R206H mutation. **J Bone Miner Res** 22 (suppl. 1); S43, 2007

Yu PB, Deng DY, Lai CS, Hong CC, Cuny GD, Boussein ML, Hong DW, McManus PM, Katagiri T, Sachidanandan C, Nobuhiro K, Fukuda T, Mishina Y, Peterson RT, Bloch KD. BMP type I receptor inhibition reduces heterotopic ossification. **Nat Med** 14, 1363-1369, 2008.

### III. SPECIAL MEDICAL CONSIDERATIONS

#### A. Introduction

Kaplan FS, Le Merrer M, Glaser DL, Pignolo RJ, Goldsby R, Kitterman JA, Groppe J, Shore EM. Fibrodysplasia ossificans progressiva (FOP). **Best Practice & Research – Clinical Rheumatology** 22: 191-205, 2008

#### B. Injury Prevention

Glaser DL, Rocke DM, Kaplan FS. Catastrophic falls in patients who have fibrodysplasia ossificans progressiva. **Clin Orthop** 346: 110-116, 1998

Lanchoney TF, Cohen RB, Rocke DM, Zasloff MA, Kaplan FS. Permanent heterotopic ossification at the injection site after diphtheria-tetanus-pertussis immunizations in children who have fibrodysplasia ossificans progressiva. **J Pediatrics** 126: 762-764, 1995

Luchetti W, Cohen RB, Hahn GV, Rocke DM, Helpin M, Zasloff M, Kaplan FS. Severe restriction in jaw movement after route injection of local anesthetic in patients who have fibrodysplasia ossificans progressiva. **Oral Surg Oral Med Oral Pathol Oral Radiol Endod** 81: 21-25, 1996

#### C. Spinal Deformity in FOP

Moore R, Dormans J, Drummond DS, Shore EM, Kaplan FS, Auerbach J. Chin-on-chest deformity in patients who have fibrodysplasia ossificans progressiva (FOP). **J Bone Joint Surg Am** 91:1497-1502, 2009

Shah P, Zasloff MA, Drummond, D, Kaplan FS. Spinal deformity in patients who have FOP. **J Bone Joint Surg Am** 76: 1442-1450, 1994

#### D. Cardiopulmonary Function in FOP

Kaplan FS, Glaser DL. Thoracic insufficiency syndrome in patients with fibrodysplasia ossificans progressiva. **Clin Rev Bone Miner Metab** 3: 213-216, 2005

Kaplan FS, Zasloff MA, Kitterman JA, Shore EM, Hong CC, Rocke DM. Early mortality and cardiorespiratory failure in patients with fibrodysplasia ossificans progressiva. **J Bone Joint Surg Am** 92: 686-691, 2010.

Kussmaul WG, Esmail AN, Sagar Y, Ross J, Gregory S, Kaplan FS. Pulmonary and cardiac function in advanced fibrodysplasia ossificans progressiva. **Clin Orthop** 346: 104-109, 1998

#### E. Immunizations & FOP

Belshe RB, Newman FK, Cannon J, Duane C, Treanor J, Van Hoecke C, Howe BJ, Dubin G. Serum antibody responses after intradermal vaccination against influenza. **New Engl J Med** 351:2286-2294, 2004

Belshe RB, Edwards KM, Vesikari T, Black SV, Walker RE, Hultquist M, Kemble G, Connor EM. CAIV-T Comparative Efficacy Study Group. Live attenuated versus inactivated influenza vaccine in infants and young children. **N Engl J Med** 356: 685-696, 2007

Cooper CL, Davis H, Cameron DW. Influenza vaccination with 1/10<sup>th</sup> the full dose. **New Engl J Med** 351: 2339-2340, 2004

General Recommendations on Immunizations: Recommendations of the Advisory Committee on Immunization Practices. **MMWR** 55(RR15):1-48, 2006.

Halperin W, Weiss WI, Altman R, et al. A comparison of the intradermal and subcutaneous routes of influenza vaccination with A/New Jersey/76 (swine flu) and A/Victoria/75: report of a study and review of the literature. **Am J Public Health** 69: 1247-1250, 1979

Hancock K, Veguilla V, Lu X, Zhong W, Butler EN, Sun H, et al. Cross-reactive antibody responses to the 2009 pandemic H1N1 influenza virus. **N Engl J Med** 361: 1945-1952, 2009.

Jain S, Kamimoto L, Bramley AM, Schmitz AM, Benoit SR, Louie J, et al. Hospitalized patients with 2009 H1N1 influenza in the United States, April-June 2009. **N Engl J Med** 361:1935-1944, 2009.

Kenney RT, Frech SA, Muenz LR, Villar CP, Glenn GM. Dose sparing with intradermal injection of influenza vaccine. **New Engl J Med** 351: 2295-2301, 2004

La Montagne JR & Fauci AS. Intradermal influenza vaccination – can less be more? **New Engl J Med** 351: 2330-2332, 2004

Lanchoney TF, Cohen RB, Rocke DM, Zasloff MA, Kaplan FS. Permanent heterotopic ossification at the injection site after diphtheria-tetanus-pertussis immunizations in children who have fibrodysplasia ossificans progressiva. **J Pediatrics** 126: 762-764, 1995

Monto AS, Ohmit SE, Petrie JG, Johnson E, Truscon R, Teich E, et al. Comparative efficacy of inactivated and live attenuated influenza vaccines. **N Engl J Med** 361: 1260-1267, 2009

Moscona A. Neuraminidase inhibitors for influenza. **N Engl J Med** 353: 1363-1373, 2005

Pearson H. Diluted flu vaccine works well. [news@nature.com](http://news@nature.com). Published online November 4, 2004

Scarlett RF, Rocke DM, Kantanie S, Patel JB, Shore EM, Kaplan FS. Influenza-like viral illnesses and flareups of fibrodysplasia ossificans progressiva. **Clin Orthop** 423:275-279, 2004

Wenzel RP, Edmond MB. Preparing for 2009 H1N1 influenza (editorial). **N Engl J Med** 361:1991-1993, 2009.

## **F. Limb Swelling & FOP**

Moriatis JM, Gannon FH, Shore EM, Bilker W, Zasloff M, Kaplan FS. Limb swelling in patients who have fibrodysplasia ossificans progressiva. **Clin Orthop Rel Res** 336: 247-253, 1997

## **G. Pressure Sores in FOP**

Mayo Clinic. Bed sores (pressure sores). <http://www.mayoclinic.com/health/bedsores/DS00570> (2008)

Kantanie S (Editor). **What is Fibrodysplasia Ossificans Progressiva (FOP)?: A Guidebook for Patients & Families.** Third Edition, International FOP Association (IFOPA), Winter Springs, Florida, 2008

Reddy M, Gill SS, Rochon PA. Preventing pressure ulcers: a systemic review. **JAMA** 296: 974-984, 2006

Thomas DR. Issues and dilemmas in the prevention and treatment of pressure ulcers: a review. **J Gerontology** 56A: M328-M340, 2001

## **H. Fractures & FOP**

Einhorn TA, Kaplan FS. Traumatic fractures of heterotopic bone in patients who have fibrodysplasia ossificans progressiva. **Clin Orthop Rel Res** 308: 173-177, 1994

## **I. Preventive Oral Healthcare in FOP**

Carvalho DR, Farage L, Martins BJ, Speck-Martins CE, Craniofacial findings in fibrodysplasia ossificans progressiva: computerized tomography evaluation. **Oral Surg Oral Med Oral Pathol Oral Radiol Endod.** 111:499-502, 2011

Connor JM & Evans DA. Extra-articular ankylosis in fibrodysplasia ossificans progressiva. **Br J Oral Surg** 20: 117-121, 1982

Donly KJ. Fluoride Varnishes. **J Calif Dental Assoc.** March, 2003

Lin R, Hildebrand T, Donly KJ. *In vitro* remineralization associated with a bioerodible fluoridated resin and a fluoride varnish. **Am J Dentist** 22: 203-205, 2009

Luchetti W, Cohen RB, Hahn GV, Rocke DM, Helpin M, Zasloff M, Kaplan FS. Severe restriction in jaw movement after route injection of local anesthetic in patients who have fibrodysplasia ossificans progressiva. **Oral Surg Oral Med Oral Pathol Oral Radiol Endod** 81: 21-25, 1996

Nussbaum BL. Dental care for patients who are unable to open their mouths. **Dental Clin North Am.** 53: 323-328, 2009.

Nussbaum BL, Grunwald Z, Kaplan FS. Oral and dental healthcare and anesthesia for persons with fibrodysplasia ossificans progressiva. **Clin Rev Bone Miner Metab** 3: 239-242, 2005

Renton P, Parkin SF, Stamp TC. Abnormal temporomandibular joints in fibrodysplasia ossificans progressiva. **Br J Oral Surg** 230: 31-38. 1982

Young JM, Diecidue RJ, Nussbaum BL. Oral management in a patient with fibrodysplasia ossificans progressiva. **Spec Care Dentist** 27: 101-104, 2007

## **J. Dental Anesthesia in FOP**

Luchetti W, Cohen RB, Hahn GV, Rocke DM, Helpin M, Zasloff M, Kaplan FS. Severe restriction in jaw movement after route injection of local anesthetic in patients who have fibrodysplasia ossificans progressiva. **Oral Surg Oral Med Oral Pathol Oral Radiol Endod** 81: 21-25, 1996

Nussbaum BL, Grunwald Z, Kaplan FS. Oral and dental healthcare and anesthesia for persons with fibrodysplasia ossificans progressiva. **Clin Rev Bone Miner Metab** 3: 239-242, 2005

Nussbaum BL, O'Hara, I, Kaplan FS. Fibrodysplasia ossificans progressiva: report of a case with guidelines for pediatric dental and anesthetic management. **ASDC J Dent Child** 63: 448-450, 1996

## **K. General Anesthesia in FOP**

Nussbaum BL, Grunwald Z, Kaplan FS. Oral and dental healthcare and anesthesia for persons with fibrodysplasia ossificans progressiva. **Clin Rev Bone Miner Metab** 3: 239-242, 2005

Tumolo M, Moscatelli A, Silvestri G. Anaesthesia management of child with fibrodysplasia ossificans progressiva. **Br J Anaesth** 97: 701-703, 2006

## **L. Orthodontics & FOP**

Luchetti W, Cohen RB, Hahn GV, Rocke DM, Helpin M, Zasloff M, Kaplan FS. Severe restriction in jaw movement after route injection of local anesthetic in patients who have fibrodysplasia ossificans progressiva. **Oral Surg Oral Med Oral Pathol Oral Radiol Endod** 81: 21-25, 1996

## **M. Submandibular Flare-ups of FOP**

Janoff HB, Zasloff MA, Kaplan FS. Submandibular swelling in patients with fibrodysplasia ossificans progressiva. **Otolaryngol Head Neck Surg** 114: 599-604, 1996.

Leavitt BD, Teeple TJ, Viozzi CF. Submandibular space swelling in a patient with fibrodysplasia ossificans progressiva: a diagnostic dilemma. **J Oral Maxillofac Surg** 67: 668-673, 2009.

## **N. Hearing Impairment in FOP**

Levy CE, Lash AT, Janoff HB, Kaplan FS. Conductive hearing loss in individuals with fibrodysplasia ossificans progressive. **Am J Audiol** 8: 29-33, 1999

## **O. Kidney Stones & FOP**

Glaser DL, Kaplan FS. Treatment considerations for the management of fibrodysplasia ossificans progressiva. **Clin Rev Bone Miner Metab** 3: 243-250, 2005



## **P. Rehabilitation Issues in FOP**

Levy CE, Berner TF, Bendixen R. Rehabilitation for individuals with fibrodysplasia ossificans progressiva. **Clin Rev Bone Miner Metab** 3: 251-256, 2005

Levy CE, Berner TF, Sandhu PS, McCarty B, Denniston MA. Mobility challenges and solutions for fibrodysplasia ossificans progressiva. **Arch Phys Med Rehab** 80: 1349-1353, 1999

## **Q. Pregnancy Issues in FOP**

Davidson BN, Bowerman RA, La Ferla JJ. Myositis ossificans progressiva and pregnancy. A therapeutic dilemma. **J Reprod Med** 30: 945-947, 1985

Thornton YS, Birnbaum SJ, Lebowitz, N. A viable pregnancy in a patient with myositis ossificans progressiva. **Am J Obstet Gynecol** 156: 577-578, 1987

#### **IV. SUMMARY OF KEY PRACTICE POINTS**

Kaplan FS, Le Merrer M, Glaser DL, Pignolo RJ, Goldsby R, Kitterman JA, Groppe J, Shore EM. Fibrodysplasia ossificans progressiva (FOP). **Best Practice & Research – Clinical Rheumatology** 22: 191-205, 2008

## V. CONCLUSIONS

Stephens T & Brynner R. **Dark Remedy**: The Impact of Thalidomide And Its Revival as a Vital Medicine. Perseus Books, 208 pages, 2001

## **X. THE INTERNATIONAL CLINICAL CONSORTIUM ON FIBRODYSPLASIA OSSIFICANS PROGRESSIVA**

(R = Research Associate)

Jaimo Ahn, M.D.  
Department of Orthopaedic Surgery  
University of Pennsylvania Medical Center  
2 Silverstein  
3400 Spruce Street  
Philadelphia, PA 19104  
Tel: 215-662-3374  
Fax: 215-349-5928  
Email: [Jaimo.ahn@uphs.upenn.edu](mailto:Jaimo.ahn@uphs.upenn.edu)

Benjamin Alman, M.D., FRCSC  
Head, Division of Orthopaedic Surgery  
The Hospital for Sick Children  
555 University Avenue  
Toronto, Ontario  
Canada M5G 1X8  
Tel: 416-813-7980  
Fax: 416-813-6414  
Email: [benjamin.alman@sickkids.ca](mailto:benjamin.alman@sickkids.ca)

Darko Anticevic, M.D.  
Professor  
Department of Orthopaedics  
University of Zagreb School of Medicine  
Salata 6, 10000 Zagreb  
Croatia  
Tel: +385-1-4819911  
Email: [darko.anticevic@zg.htnet.hr](mailto:darko.anticevic@zg.htnet.hr)

John Stephen Bamforth, M.D.  
Department of Medical Genetics  
8-53 Medical Sciences building  
University of Alberta Hospital  
Edmonton, Alberta T6G 2H7  
Canada  
Tel: 780-407-7327  
Fax: 780-407-6845  
Email: [sbamfort@cha.ab.ca](mailto:sbamfort@cha.ab.ca)

Dr. Genevieve Baujat  
Centre de Référence Maladies Osseuses Constitutionnelles  
Département de Génétique  
Hôpital Necker-Enfants Malades  
Paris, France  
Tel: (secretariat): 003344495153; Office: 003371196418  
Email: [genevieve.baujat@nck.aphp.fr](mailto:genevieve.baujat@nck.aphp.fr)

Jonathan Bernstein, M.D.  
Director  
Children's Center for Cancer & Blood Diseases of Las Vegas  
1090 E. Desert Inn - Suite 200  
Las Vegas, NV 89109  
Tel: 702-732-1493  
Fax: 702-732-1080  
Email: [jonbern1@aol.com](mailto:jonbern1@aol.com)

Cindy Blifeld, M.D.  
Lompoc Valley Pediatric Care Center, Inc.  
1111 East Ocean Avenue #6  
Lompoc, CA 93436  
Tel: 805-736-4970  
Fax: 805-736-7592  
Email: [CindyBlifeldMD@lvpc.com](mailto:CindyBlifeldMD@lvpc.com)

Tae-Joon Cho, M.D.  
Professor  
Division of Pediatric Orthopaedics  
Seoul National University Children's Hospital  
101 Daehang-ro Jongno-gu  
Seoul 110-744  
Republic of Korea  
Tel: +82-2-2072-2878  
Fax: +82-2-745-3367  
Email: [tjcho@snu.ac.kr](mailto:tjcho@snu.ac.kr) / [tjcho.pos@gmail.com](mailto:tjcho.pos@gmail.com)

In Ho Choi, M.D.  
Professor  
Division of Pediatric Orthopaedics  
Seoul National University Children's Hospital  
101 Daehang-ro Jongno-gu  
Seoul 110-744  
Republic of Korea  
Tel: +82-2-2072-3640  
Fax: +82-2-745-3367  
Email: [inhoc@snu.ac.kr](mailto:inhoc@snu.ac.kr)

Felicity Collins, M.D.  
Clinical Geneticist  
Head, Dept of Clinical Genetics  
Western Sydney Genetics Program  
Dept of Clinical Genetics  
Children's Hospital At Westmead  
Locked Bag 4001  
Westmead NSW 2145  
AUSTRALIA  
Tel: +61-2-9845-3273  
Fax: + 61-2-9845-3204  
Email: [felicic2@chw.edu.au](mailto:felicic2@chw.edu.au)

Douglas Colmenares Bonila, M.D.  
Pediatric Orthopedic Surgeon  
Hospital Regional De Alta Especialidad Del Bajio  
Guanajuato, Mexico  
Tel: (52) 477 788 5611 or (52) 477 638 9862  
Fax: (52) 477 7885711  
Email: [douglas\\_cb@yahoo.com](mailto:douglas_cb@yahoo.com)

Carmen L. De Cunto, M.D.  
Professor and Chief  
FOP Clinical Advisor, Argentina  
Pediatric Rheumatology Section  
Department of Pediatrics  
Hospital Italiano de Buenos Aires  
Gascón 450, 1181  
Ciudad Autónoma de Buenos Aires  
Argentina  
Tel: +5411-4959-0578  
Fax: +5411-4959-0577  
Email: [carmen.decunto@hospitalitaliano.org.ar](mailto:carmen.decunto@hospitalitaliano.org.ar)

Patricia L. R. Delai, M.D.  
Orthopaedic Department of Santa Casa de Misericórdia de  
São Paulo School of Medicine  
Faculdade de Ciências Médicas da Santa Casa de São Paulo –  
Departamento de Ortopedia  
Rua Pedro de Toledo 129 cj 121 - Vila Clementino  
Cep: 04039-001  
São Paulo,  
Brazil  
Tel: +55-11-5539-5817 (office) or +55-11- 9658-8816 (cell) or +55-11-3501-1891 (home)  
Email: [patriciadelai@uol.com.br](mailto:patriciadelai@uol.com.br)

Martin Delatycki, M.D.  
Associate Professor  
Director, Bruce Lefroy Centre for Genetic Health Research  
Clinical Geneticist, Genetic Health Services  
Victoria Murdoch Children's Research Institute  
Royal Children's Hospital  
Flemington Road  
Parkville, 3052  
Victoria  
Australia  
Tel: +61-3-8341-6284  
Fax: +61-3-8341-6390  
Email: [martin.delatycki@ghsv.org.au](mailto:martin.delatycki@ghsv.org.au)

Maja DiRocco, M.D.  
Unit of Rare Diseases  
Department of Pediatrics Gaslini Institute  
Largo Gaslini 3  
16147 Genoa  
Italy  
Tel: +39-010-563-6794  
Fax: +39-010-563-6211  
Email: [majadirocco@ospedale-gaslini.ge.it](mailto:majadirocco@ospedale-gaslini.ge.it)

E.M.W. Eekhoff, M.D., Ph.D.  
VU Medical Center Amsterdam  
Department of Internal Medicine/Section Endocrinology  
De Boelelaan 1117  
1081HV Amsterdam  
The Netherlands  
Tel: +31-20-4440588  
Email: [EMW.Eekhoff@vumc.nl](mailto:EMW.Eekhoff@vumc.nl)

Thomas A. Einhorn, M.D.  
Professor and Chairman  
Department of Orthopaedic Surgery  
Boston University School of Medicine  
720 Harrison Avenue, Suite 808  
Boston, MA 02118  
Tel: 617-638-8435  
Fax: 617-638-8493  
Email: [thomas.einhorn@bmc.org](mailto:thomas.einhorn@bmc.org)

Ellen R. Elias, M.D.  
Special Care Clinic  
The Children's Hospital  
University of Colorado at Denver & Health Sciences Center  
13123 E. 16<sup>th</sup> Avenue  
Aurora, Colorado 80045  
Tel: 720-777-6739  
Fax: 720-777-7143  
Email: [Elias.Ellen@tchden.org](mailto:Elias.Ellen@tchden.org)

Frank Gannon, M.D. (R)  
Associate Professor of Pathology & Immunology, and Orthopedic Surgery  
Baylor College of Medicine  
Director, Residency & Fellowship Programs  
Department of Pathology & Immunology  
1 Baylor Plaza, Suite 286A  
Houston, Texas 77030  
Tel: 713-798-4340/Cell: 281-386-6909  
Email: [fgannon@bcm.edu](mailto:fgannon@bcm.edu)

Gabriele Gillessen-Kasebach, M.D.  
Professor and Chair of Genetics  
Institut für Humangenetik Lübeck  
Universitätsklinikum Schleswig-Holstein  
Ratzeburgeralle 160  
D-23538 Lübeck  
Germany  
Tel: +494515002620  
Fax: +494515004187  
Email: [g.gillessen@uk-sh.de](mailto:g.gillessen@uk-sh.de)

David L. Glaser, M.D.  
Assistant Professor  
Department of Orthopaedic Surgery  
University of Pennsylvania Health System  
Presbyterian Hospital/1 Cupp  
39th and Market Street  
Philadelphia, PA 19104  
Tel: 215-349-8735/Cell: 215-510-3261  
Fax: 215-349-5928  
E-mail: [david.glaser@uphs.upenn.edu](mailto:david.glaser@uphs.upenn.edu)

Robert Goldsby, M.D.  
Associate Professor  
Department of Pediatrics, Division of Pediatric Hematology/Oncology  
Box 0106  
University of California San Francisco  
San Francisco, CA 94143-0734  
Tel: 415-476-3831  
Fax: 415-502-4372  
Email: [goldsbyr@peds.ucsf.edu](mailto:goldsbyr@peds.ucsf.edu)

Jay Groppe, Ph.D. (R)  
Associate Professor  
Department of Biomedical Sciences  
Baylor College of Dentistry  
Texas A & M University Health Science Center  
3302 Gaston Avenue  
Dallas, Texas 75246  
Tel: 214-370-7203 (office) or 214-370-7212 (laboratory)  
Fax: 214-874-4538  
Email: [jgroppe@bcd.tamhsc.edu](mailto:jgroppe@bcd.tamhsc.edu)

Nobuhiko Haga, M.D.  
Professor  
Department of Rehabilitation Medicine  
Graduate School of Medicine  
The University of Tokyo  
7-3-1 Hongo, Bunkyo-ku  
Tokyo 113-8655  
Japan  
Tel: +81-3-5800-8795  
Fax: +81-3-5684-2094  
Email: [hagan-reh@h.u-tokyo.ac.jp](mailto:hagan-reh@h.u-tokyo.ac.jp)

Kathleen A. Haines, M.D.  
Section Chief  
Pediatric Immunology  
Pediatric Rheumatology & Immunology  
Hackensack University Medical Center  
30 Prospect Avenue  
Hackensack, NJ 07601  
Tel: 201 996 5306  
Fax: 201 996 9815  
Email: [KHaines@humed.com](mailto:KHaines@humed.com)

Peter Hammond, M.D. (R)  
Professor of Computational Biology  
Molecular Medicine Unit  
UCL Institute of Child Health  
30 Guilford St  
London WC1N 1EH  
UK  
Tel: +44 (0)207 905 2399  
Unit administrator: +44 (0)20 7905 2159  
Fax: +44 (0)20 7404 6191  
Email: [p.hammond@ucl.ac.uk](mailto:p.hammond@ucl.ac.uk)

Charles C. Hong, M.D., Ph.D.  
Assistant Professor  
Department of Medicine  
Vanderbilt University School of Medicine  
2220 Pierce Avenue  
383 Preston Research Building  
Nashville, TN 37232  
Research Medicine  
Veterans Affairs TVHS  
Nashville, TN 37212  
Tel: 615-936-7032; Cell: 615-332-1402  
Email: [charles.c.hong@vanderbilt.edu](mailto:charles.c.hong@vanderbilt.edu)



Julie Hoover-Fong, M.D., Ph.D.  
Clinical Director  
Greenberg Center for Skeletal Dysplasias  
McKusick-Nathans Institute of Genetic Medicine  
Johns Hopkins University  
600 N. Wolfe Street – Blalock 1008  
Baltimore, MD 21287  
Tel: 410- 955-3071  
Fax: 410-502-2375  
Email: [jhoover2@jhmi.edu](mailto:jhoover2@jhmi.edu)

Edward Hsiao, M.D. Ph.D.  
Department of Endocrinology, Faculty Practice  
University of California-San Francisco  
400 Parnassus Ave., 5<sup>th</sup> Floor A550  
UCSF Box 1222  
San Francisco, CA 94143-1222  
Tel: 415-353-2350: Office phone (for research-related questions): 415- 476-9732  
Email: [edward.hsiao@ucsf.edu](mailto:edward.hsiao@ucsf.edu)

Masahiro Iwamoto, Ph.D. (R)  
Research Professor  
Children's Hospital of Philadelphia Research Institute  
Abramson Research Center - Suite 902  
3615 Civic Center Boulevard  
Philadelphia, PA 19104  
Tel: 267-425-2072  
Email: [iwamotom@email.chop.edu](mailto:iwamotom@email.chop.edu)

Frederick S. Kaplan, M.D.  
Isaac and Rose Nassau Professor of Orthopaedic Molecular Medicine  
Director, Center for Research in FOP & Related Disorders  
The University of Pennsylvania School of Medicine  
Hospital of The University of Pennsylvania  
Department of Orthopaedic Surgery  
Silverstein Pavilion - Second Floor  
3400 Spruce Street  
Philadelphia, PA 19104, USA  
Tel: (Office) 215-349-8726/8727 or (Home) 215-545-0758  
Fax: 215-349-5928  
Email: [frederick.kaplan@uphs.upenn.edu](mailto:frederick.kaplan@uphs.upenn.edu)

Takenobu Katagiri, Ph.D. (R)  
Head and Professor  
Division of Pathophysiology  
Research Center for Genomic Medicine  
Saitama Medical University  
1397-1 Yamane, Hidaka-shi  
Saitama 350-1241  
Japan  
Tel: +81-42-984-0443  
Fax: +81-42-984-4651  
Email: [katagiri@saitama-med.ac.jp](mailto:katagiri@saitama-med.ac.jp)

Joseph A. Kitterman, M.D.  
Professor Emeritus  
Department of Pediatrics and Cardiovascular Research Institute  
U-503, Box 0734  
University of California San Francisco  
San Francisco, CA 94143-0734  
Tel: 415-383-3471  
Fax: 415-476-6679.  
Email: [j-kitterman@att.net](mailto:j-kitterman@att.net)

Craig B. Langman, M.D.  
The Isaac A. Abt M.D. Professor of Kidney Diseases  
Feinberg School of Medicine  
Northwestern University  
Head, Kidney Diseases, Children's Memorial Hospital  
2300 Children's Plaza #37  
Chicago IL 60614  
Executive Secretary: Debbie Muse ([dmuse@childrensmemorial.org](mailto:dmuse@childrensmemorial.org))  
Tel: 773-327-5071  
Fax: 773-327-5072  
DaVita Children's Dialysis: 773-549-2010  
Email: [c-langman@northwestern.edu](mailto:c-langman@northwestern.edu)

Mona LaPlant, M.D. M.S.  
Rheumatology  
Children's Hospitals and Clinics of Minnesota  
Garden View Medical Building  
347 North Smith Avenue - Suite 504: Room 5007  
St Paul, MN 55102  
Tel: direct: 651-220-6137 or office: 651-220-6444  
Fax: 651-220-7233  
Email: [Mona.LaPlant@childrensmn.org](mailto:Mona.LaPlant@childrensmn.org)

Shio Jean Lin, M.D.  
Vice Dean for Medical Education  
Professor in Pediatrics  
National Cheng Kung University School of Medicine  
Deputy Superintendent  
National Cheng Kung University Hospital  
138 Sheng-Li Road  
Tainan 70428  
Taiwan  
Tel: +886-6-2353535 X 2002 or 5286  
Fax: +886-6-2097950 or 886-6-2380519

Frank P. Luyten, MD, PhD  
Professor and Chairman  
Division of Rheumatology  
University Hospitals Leuven  
Herestraat 49 Gasthuisberg  
B 3000 Leuven, Belgium  
Tel: + 32-16342541  
Fax: + 32-16342543  
Email: [Frank.luyten@uzleuven.be](mailto:Frank.luyten@uzleuven.be)

Jim McGill, M.D.  
Clinical Geneticist  
Director, Department of Metabolic Medicine  
Royal Children's Hospital  
Ground Floor, Surgical Building  
Herston Road  
Herston, Queensland 4029  
Australia  
Tel: +61-7-3636-8176  
Fax: + 61-7-3636-5505  
Email: [Jim\\_McGill@health.qld.gov.au](mailto:Jim_McGill@health.qld.gov.au)

Fergus E. McKiernan, M.D.  
Center for Bone Diseases  
Marshfield Clinic  
1000 N. Oak Avenue  
Marshfield, Wisconsin 54449  
Tel: 715-389-7730  
Fax: 715-387-5644  
Email: [mckiernan.fergus@marshfieldclinic.org](mailto:mckiernan.fergus@marshfieldclinic.org)

Ralph J. Marino, M.D., M.S., F.A.C.R.M.  
Professor  
Department of Rehabilitation Medicine  
Jefferson Medical College of Thomas Jefferson University  
132 South 10<sup>th</sup> Street  
Suite 375 - Main Building  
Philadelphia, PA 19107  
Tel: 215-955-5756  
Fax: 215-955-5152  
Email: [ralph.marino@jefferson.edu](mailto:ralph.marino@jefferson.edu)

Mario I. Martinez, M.D.  
Pediatrics  
Providence Community Health Centers  
CHAFEE Health Center  
1 Warren Way  
Providence, Rhode Island 02905  
Tel: 401-444-0530  
Fax: 401-444-0423

Deanna Mitchell, M.D.  
Attending Pediatric Hematologist-Oncologist  
DeVos Children's Hospital  
Pediatric Hematology/Oncology  
100 Michigan NE  
Grand Rapids, MI 49503  
Tel: 616-391-2086  
Fax: 616-391-8873  
E-mail: [deanna.mitchell@devoschildrens.org](mailto:deanna.mitchell@devoschildrens.org)

Antonio Morales Piga, M.D.  
Jefe de Servicio de Proyectos Clínicos  
Instituto de Investigación de Enfermedades Raras  
Instituto de Salud Carlos III  
C) Sinesio Delgado, 6; 28029 Madrid.  
España  
Tel: +34-91-8222023  
Email: [amorales@isciii.es](mailto:amorales@isciii.es)

Rolf Morhart, M.D.  
Medical Director  
Department of Pediatrics  
Klinikum Garmisch-Partenkirchen GmbH  
Auenstraße 6  
D-82467 Garmisch-Partenkirchen  
Germany  
Tel: +49-(0)8821/77-1350  
Fax: +49-(0)8821/77-1351  
Email: [rolf.morhart@Klinikum-gap.de](mailto:rolf.morhart@Klinikum-gap.de)

Geert Mortier, M.D., Ph.D.  
Head, Department of Medical Genetics  
Professor of Medical Genetics  
Antwerp University & Hospital  
Prins Boudewijnlaan 43  
B-2650 Edegem  
Belgium  
Phone: +32-(0)3-2759773 (secretary); +32-(0)3-2759766 (direct)  
Fax: +32-(0)3-2759723`  
Email: [geert.mortier@ua.ac.be](mailto:geert.mortier@ua.ac.be)

Mary Mullins, Ph.D. (R)  
Professor  
Department of Cell & Developmental Biology  
The University Pennsylvania School of Medicine  
1211 BRB II/III  
421 Curie Boulevard  
Philadelphia, PA 19104-6058  
Tel: 215-898-2644  
Fax: 215-898-9871  
Email: [mullins@mail.med.upenn.edu](mailto:mullins@mail.med.upenn.edu)

Stefan Mundlos, M.D.  
Director  
Institut für Medizinische Genetik und Humangenetik  
Charité – Universitätsmedizin Berlin  
Augustenburger Platz 1  
13353 Berlin  
Germany  
Tel: +49-30-450-569-122  
E-mail: [stefan.mundlos@charite.de](mailto:stefan.mundlos@charite.de)

Sheela Nampoothiri, Dip NB (Paed), DCH, MSc Medical Genetics  
Consultant  
Department of Pediatric Genetics,  
Amrita Institute of Medical Sciences & Research Center,  
AIMS Ponekkara PO,  
Cochin 682041  
Kerala  
India  
Tel: +0484-2801234  
Fax: +0484-2802020  
Email: [sheelanampoothiri@aims.amrita.edu](mailto:sheelanampoothiri@aims.amrita.edu); [sheeladr@gmail.com](mailto:sheeladr@gmail.com)

Coen Netelenbos, M.D., Ph.D.  
Professor  
Departments of Medicine and Genetics  
Division of Endocrinology  
University Hospital Vrije Universiteit  
De Boelelaan 1117/ P.O. Box 7057  
1007 MB Amsterdam  
The Netherlands  
Tel: +31-20-444-0530  
E-mail: [c.netelen@vumc.nl](mailto:c.netelen@vumc.nl)

Dau-Ming Niu, M.D., Ph.D.  
Director, Medical Genetic Center of Taipei  
Veterans General Hospital  
Associate Professor, Institute of Clinical Medicine  
National Yang-Ming University  
No. 201, Sec. 2, Shih-Pai Road  
Taipei 112, Taiwan  
Tel: +886-2-66115889  
Fax: +886-2-28767181  
Email: [dmniu1111@yahoo.com.tw](mailto:dmniu1111@yahoo.com.tw)

Regis O'Keefe, M.D., Ph.D.  
Chairman of URM C's Department of Orthopaedics and Rehabilitation  
University of Rochester  
School of Medicine and Dentistry  
601 Elmwood Ave, Box 665  
Rochester, New York 14642  
Tel: 585-275-5167  
Fax: 585 756-4727  
Email: [Regis\\_okeefe@urmc.rochester.edu](mailto:Regis_okeefe@urmc.rochester.edu)

Maurizio Pacifici, Ph.D. (R)  
Professor of Orthopaedic Surgery  
Division of Orthopaedic Surgery  
Children's Hospital of Philadelphia Research Institute  
Abramson Research Center - Suite 902D  
3615 Civic Center Boulevard  
Philadelphia, PA 19104  
Tel: 267-425-2073  
Email: [pacificim@email.chop.edu](mailto:pacificim@email.chop.edu)

Annette Perea, M.D.  
9317 Roosevelt Avenue  
Jackson Heights, NY 11372  
Tel: 718- 446-0270  
Fax: 718 446-5939  
Email: [alainasosa@aol.com](mailto:alainasosa@aol.com)

Robert J. Pignolo, M.D., Ph.D.  
Assistant Professor  
Director, Ralston-Penn Clinic for Osteoporosis & Related Bone Disorders  
Ian Cali Clinical & Research Scholar, Center for FOP and Related Bone Disorders  
Departments of Medicine & Orthopaedic Surgery  
University of Pennsylvania School of Medicine  
424B Stemmler Hall  
36th Street & Hamilton Walk  
Philadelphia, PA 19104-6081  
Tel: 215-746-8138 or 215-898-8653  
Fax: 215-573-2133  
Email: [pignolo@mail.med.upenn.edu](mailto:pignolo@mail.med.upenn.edu)

Roberto Ravazzolo, M.D. (R)  
Professor  
Laboratory of Molecular Genetics  
G. Gaslini Institute  
Department of Pediatrics and CEBR  
University of Genova  
Largo G. Gaslini 5  
16148 Genova  
Italy  
Tel: +39-010-5636370; +39-010-563-6400  
Fax: +39-010-377-9797  
Email: [rravazzo@unige.it](mailto:rravazzo@unige.it)

David M. Rocke, Ph.D. (R)  
Distinguished Professor  
Division of Biostatistics  
School of Medicine  
University of California-Davis  
One Shields Avenue  
Davis, California 95616  
Tel: 530-752-6999  
E-mail: [dmrocke@ucdavis.edu](mailto:dmrocke@ucdavis.edu)

Eric Ronge, M.D.  
Consultant Pediatrician  
Pediatric Department  
Central Hospital  
SE-54185  
Skönde, Sweden  
Tel: +46-500-431-000 or +46-500-432-295  
Fax: +46-500-432-029  
Email: [eric.ronge@vgregion.se](mailto:eric.ronge@vgregion.se)

Ravi Savarirayan M.D. (Melb.), B.S. (Adel.), F.R.A.C.P., A.R.C.P.A. (Hon.)  
Professor and Chief, Clinical Genetics Services  
Victorian Clinical Genetics Service  
Murdoch Children's Research Institute  
Royal Children's Hospital  
Flemington Road  
Parkville, Victoria 3052  
Australia  
Tel: +61-(03)-8341-6244  
Fax: +61-(03)-8341-6390  
Email: [ravi.savarirayan@mcri.edu.au](mailto:ravi.savarirayan@mcri.edu.au); URL [www.mcri.edu.au](http://www.mcri.edu.au)

Sujata Sawhney, M.D. (Pediatrics), M.R.C.P. (U.K.), C.C.S.T (U.K.)  
Grad. Cert. P. Rheum. (Australia)  
Consultant Pediatric and Adolescent Rheumatologist  
Pediatric Rheumatology Division - Center for Child Health  
Sir Ganga Ram Hospital  
New Delhi 110022  
India  
Tel: +91-98-11-444-116  
Email: [drsujatasawhney@gmail.com](mailto:drsujatasawhney@gmail.com)

Christiaan Scott, MBChB, FCPaed (SA)  
Paediatric Rheumatologist  
Red Cross Children's Hospital  
Cape Town 7700  
South Africa  
Tel: +27-21-6585503. Mobile: +27845805473  
Email: [christiaanscott@gmail.com](mailto:christiaanscott@gmail.com) or [chris.scott@uct.ac.za](mailto:chris.scott@uct.ac.za)

Astrid Schulze, M.D.  
Consultant Pediatrician/Pediatric Neurologist  
Child Neuro/Disability Service Sofievägen 2  
University Hospital  
SE-222-41  
Lund, Sweden  
Tel: +46-46-770-761 or +46-46-770-709  
Fax: +46-46-770-710  
Email: [astridschulze@mail.dk](mailto:astridschulze@mail.dk)

Petra Seemann, Ph.D. (R)  
Berlin-Brandenburg Center for Regenerative Therapies (BCRT)  
Charité – Universitätsmedizin Berlin  
Augustenburger Platz 1  
13353 Berlin  
Germany  
Phone: +49-30-450-539-436  
Fax: +49-30-450-7-539-436  
E-mail: [petra.seemann@charite.de](mailto:petra.seemann@charite.de)

Eileen M. Shore, Ph.D. (R)  
Research Professor  
Departments of Orthopaedic Surgery and Genetics  
Co-Director, Center for Research in FOP & Related Disorders  
Director, FOP Laboratory  
The University of Pennsylvania School of Medicine  
424 Stemmler Hall  
36th & Hamilton Walk  
Philadelphia, PA 19104  
Tel: 215-898-2330/2331  
Fax: 215-573-2133  
E-mail: [shore@mail.med.upenn.edu](mailto:shore@mail.med.upenn.edu)

Steven Schuss, M.D.  
Pediatrics  
197 Cedar Lane  
Teaneck, NJ 07666  
Tel: 201-836-7171  
Fax: 201-928-4227

David Sillence, M.D. F.R.A.C.P. F.A.F.R.M. (Hon)  
Professor of Medical Genetics  
Head of Connective Tissue Dysplasia Clinic  
The Children's Hospital at Westmead  
Locked Bag 4001  
Westmead NSW 2145  
Sydney, Australia  
And  
Department of Genetic Medicine Westmead Hospital (adults)  
Westmead NSW 2145  
Sydney, Australia  
Tel: +61-2-9845-0000  
Fax: +61-2-9845-3489  
Email: [davids@chw.edu.au](mailto:davids@chw.edu.au)

Roger Smith, M.D.  
Honorary Consultant Physician  
Nuffield Orthopaedic Centre  
Windmill Road  
Headington  
Oxford OX3 7LD  
England  
United Kingdom  
Tel: +44-186-579-0800  
Email: [Ann.Burrows@ndos.ox.ac.uk](mailto:Ann.Burrows@ndos.ox.ac.uk)

Elizabeth A. Szalay, M.D.  
Professor, Pediatric Orthopaedic Surgery and Pediatrics  
Chief, Division of Pediatric Orthopaedics  
University of New Mexico Health Sciences Center  
1127 University Boulevard, NE  
Albuquerque, NM 87102  
Tel: 505-272-5214  
Fax: 505-272 6500  
Email: [ESzalay@salud.unm.edu](mailto:ESzalay@salud.unm.edu)

Jeffrey Tabas, M.D.  
Director Performance Improvement  
San Francisco General Hospital Emergency Services  
Associate Professor  
UCSF School of Medicine  
505 Parnassus Avenue, L138, Box 0208  
San Francisco, CA 94143  
Tel: 415-206-5759  
Fax: 415-206-5818  
Email: [jeff.tabas@emergency.ucsf.edu](mailto:jeff.tabas@emergency.ucsf.edu)

James T. Triffitt, Ph.D. (R)  
Professor  
Institute of Musculoskeletal Sciences  
Botnar Research Centre  
Nuffield Department of Orthopaedic Surgery  
University of Oxford  
Nuffield Orthopaedic Centre  
Oxford OX3 7LD, United Kingdom  
Tel: +44-1865-227660  
Fax: +44-1865-227673  
Email: [james.triffitt@ndos.ox.ac.uk](mailto:james.triffitt@ndos.ox.ac.uk)

Pernille Tryli, M.D.  
Attending Pediatric Physician  
Tryli Atna  
Hedark N-2476  
Norway  
Tel: + 0047-97188496  
E-mail: [pernille.tryli@sykehuset-innlandet.no](mailto:pernille.tryli@sykehuset-innlandet.no)

Heinz Unterböersch, M.D.  
Attending Orthopaedic Surgeon  
Orthopädische Praxis  
Friedrich-Offermann-Strasse 5  
51429 Bergisch Gladbach  
Bensberg  
Germany  
Tel: +49-2204-51027  
Fax: +49-2204-51028



J. Andoni Urtizberea, M.D.  
Assistance Publique - Hôpitaux de Paris (AP-HP)  
Attending Physician of Physical Medicine and Rehabilitation  
Hospital Marin  
Route de la Corniche  
64700 Hendaye  
France  
Tel: +33-(0)5-59-48-2686  
E-mail: [andoni.urtizberea@hnd.aphp.fr](mailto:andoni.urtizberea@hnd.aphp.fr)

Anders Wallin, M.D.  
Chief of Pediatrics  
Mälarsjukhuset  
Barn-och ungdomskliniken  
631 88 Eskilstuna  
Sweden  
Tel: (hospital) +4616103000/cell: +46708776640  
Email: [anders.wallin@dll.se](mailto:anders.wallin@dll.se)

Guosheng Wang, M.D.  
Associate Professor  
Department of Rheumatology  
Anhui Provincial Hospital  
17# Lujiang Road  
Hefei, 230001  
Anhui Province  
P.R. China  
Tel: +86-551-2283475  
Fax: +86-551-2283475  
Email: [gswang@mail.hf.ah.cn](mailto:gswang@mail.hf.ah.cn)

Daniel Weiler, M.D., F.C.C.P.  
Emeritus Chief, Division of Respiratory Physiology and Chest Disease,  
Carmel Medical Center  
29 Tshernichovsky Street  
Haifa 35701  
ISRAEL  
Tel: +972-4-8311576; cell: +972-545-322422  
Fax: +972-4-8338531  
Answering Service: +972-3-7543912 (Please remain online if I do not answer and you will be able to leave a message).  
Email: [weiler@actcom.co.il](mailto:weiler@actcom.co.il)

Anders Westermarck, M.D.  
Norra Esplanadgatan 13A  
AX 22100 Mariehamn  
Åland  
Finland.  
Tel: Home +358 (0)18 13114/ or Mobile phone +358 (0)457 344 2213  
E-mail: [a.h.westermarck@aland.net](mailto:a.h.westermarck@aland.net)

Kristi Wharton, Ph.D., M.S. (R)  
Associate Professor  
Department: Molecular, Cellular Biology Biochemistry  
Division of Biology & Medicine  
Brown University  
Box G- L370  
Providence, Rhode Island 02192  
Tel: 401-863-1951 or 401-863-7635  
Email: [Kristi\\_Wharton@Brown.edu](mailto:Kristi_Wharton@Brown.edu)

Michael Whyte, M.D.  
Medical-Scientific Director  
Center for Metabolic Bone Disease and Molecular Research  
Shriners Hospital for Children  
2001 South Lindbergh Boulevard  
St. Louis, MO 63131  
Tel: 314-872-8305  
Fax: 314-872-7844  
E-mail: [MWhyte@shrinenet.org](mailto:MWhyte@shrinenet.org)

Paul Wordsworth, M.D.  
Nuffield Department of Orthopaedic Surgery  
Nuffield Orthopaedic Centre  
Windmill Road  
Headington, Oxford OX3 7LD  
United Kingdom  
Tel: +44-1865-737545  
Fax: +44-1865-737640  
Email: [paul.wordsworth@clinical-medicine.oxford.ac.uk](mailto:paul.wordsworth@clinical-medicine.oxford.ac.uk)

Nicholas D. Yeager, M.D.  
Assistant Professor of Pediatrics  
Section Hematology-Oncology  
Nationwide Children's Hospital  
The Ohio State University  
700 Children's Drive  
Columbus, Ohio 43205  
Tel: 614-722-3553  
Fax: 614-722-3699  
Email: [Nicholas.Yeager@nationwidechildrens.org](mailto:Nicholas.Yeager@nationwidechildrens.org)

Michael Zasloff, M.D., Ph.D.  
Adjunct Professor  
Departments of Orthopaedic Surgery and Genetics  
The Center for Research in FOP & Related Disorders  
The University of Pennsylvania School of Medicine  
and  
Professor, Departments of Surgery and Pediatrics  
Director, Surgical Immunology  
Georgetown University  
Med/Dent NW 210  
Washington, DC 20007  
Tel: 202-687-5707 (office) or 610-617-3488 (home) or 484-433-7807 (cell)  
Fax: 202-687-0992  
Email: [maz5@georgetown.edu](mailto:maz5@georgetown.edu) or [mzasloff@aol.com](mailto:mzasloff@aol.com)

Keqin Zhang, M.D., Ph.D.  
Director, Dept. of Endocrinology  
Tongji Hospital  
Shanghai Tongji University  
389. Xin Cun Road  
Shanghai 200065  
P.R. China  
Tel:  
Fax:  
Email: [keqzhang@hotmail.com](mailto:keqzhang@hotmail.com)

**For questions on dental care for FOP patients, please contact the following consortium members:**

**For Routine Dental Care:**

Corrie Crowe, D.D.S.  
686 Stokes Road  
Medford, NJ 08055  
Tel: (office) 609-654-4331: (Cell): 407-701-3210  
Fax: 609-654-4366.  
Email: [drcrowdentistry@gmail.com](mailto:drcrowdentistry@gmail.com) or [all4th94@yahoo.com](mailto:all4th94@yahoo.com)

Burton Nussbaum, D.D.S.  
Adjunct Associate Professor, Pediatric Dentistry  
University of Pennsylvania School of Medicine  
Special Needs Dentist  
Thomas Jefferson University Medical School and Hospital  
One South Forge Lane  
Cherry Hill, NJ 08002  
Tel: (cell) 609-922-3526 (h) 856-667-8757  
Email: [bikr2th@aol.com](mailto:bikr2th@aol.com)

**For Hospital Dentistry and Dental Surgery:**

Robert Diecidue, M.D., D.M.D., M.B.A., M.S.P.H.  
Thomas Jefferson University  
Jefferson Medical College  
Department of Oral and Maxillofacial Surgery  
Chairman and Professor  
909 Walnut Street - Suite 300  
Philadelphia, Pennsylvania 19107  
Tel: 215-955-6215  
Fax: 215-923-9189  
Email: [robert.diecidue@jeffersonhospital.org](mailto:robert.diecidue@jeffersonhospital.org)

Daniel Taub, M.D., D.M.D.  
Thomas Jefferson University  
Jefferson Medical College  
Assistant Director and Instructor  
Department of Oral and Maxillofacial Surgery  
909 Walnut Street - Suite 300  
Philadelphia, Pennsylvania 19107  
Tel: 215-955-6215  
Fax: 215-923-9189  
Email: [daniel.taub@jeffersonhospital.org](mailto:daniel.taub@jeffersonhospital.org)

Allen Wong, D.D.S., D.A.B.S.C.D.  
Hospital Dentistry Program, Director  
University of the Pacific  
Arthur A. Dugoni School of Dentistry  
2155 Webster Street  
San Francisco, CA 94115  
Tel: 415-720-4609 (cell) or 888-241-3694 (emergency beeper)  
Email: [awong@pacific.edu](mailto:awong@pacific.edu)

**For questions on general anesthesia for FOP patients, please contact the following consortium member:**

Zvi Grunwald, M.D.  
The James D. Wentzler Professor and Chairman  
Department of Anesthesiology  
Thomas Jefferson University and Hospitals  
111 South 11th Street, Suite G-8490  
Philadelphia, PA 19107  
Tel: 215-955-6161  
Fax: 215-923-5507  
Email: [zvi.grunwald@jefferson.edu](mailto:zvi.grunwald@jefferson.edu)

**For questions on rehabilitation for FOP patients, please contact the following consortium members:**

Theresa F. Berner, MOT, OTR/L, ATP  
Rehabilitation Team Leader  
The Ohio State University Medical Center  
Rehabilitation Services  
2050 Kenny Road  
Suite 2100 - Martha Morehouse Medical Pavilion  
Columbus Ohio 43221  
Tel: 614 293-3847  
Fax: 614 293-6400  
Email: [Theresa.Berner@osumc.edu](mailto:Theresa.Berner@osumc.edu)

Charles Levy, M.D.  
Chief, Physical Medicine and Rehabilitation Service  
North Florida/South Georgia Veterans Health Service  
Associate Adjunct Professor, Department of Occupational Therapy  
University of Florida  
1601 S.W. Archer Road  
Gainesville, Florida 32608  
Tel: 352-374-6065  
Fax: 352-374-6116  
Email: [charles.levy@va.gov](mailto:charles.levy@va.gov)